

PARAARTICULAR CHONDROMA LOCATED ON DORSAL REGION OF THE WRIST – CASE REPORT AND REVIEW OF THE LITERATURE

Jahja Dalip¹, Manasieva Magdalena², Kaproli Indrit³, Trajanovski Aleksandar¹, Popovski Neron¹, Gavrilovski Antonio¹, Todorova Teodora¹, Samardziski Milan¹

¹University Clinic for Orthopedic Surgery, Skopje, Faculty of Medicine, Ss. Cyril and Methodius University, Skopje, Republic of North Macedonia

²General Hospital, Kochani, Republic of North Macedonia

³Medical center Ferid Murat, Gostivar, Republic of North Macedonia

e-mail: dr_dalip@hotmail.com

Abstract

Most chondromas mainly affect the body's extremities. It is really an unusual entity - the formation of an isolated chondroma around carpal bones. Paraarticular chondromas represent a rare variant form of extraskeletal chondroma.

We present a case of a 27-year-old male, who underwent a clinical examination due to a small soft tissue tumefaction in the wrist region for approximately 10 years. A clearly limited tumor formation with a solid consistency was detected on clinical examination. Dorsal flexion on the left hand was reduced to 40 degrees compared to his right wrist. X-ray showed a presence of a small bone tumor. The subsequent CT scan confirmed the more accurate extension of the mass.

Surgery was performed, the tumor was removed completely, with histology in favor of chondroma. No immobilization was required and the active range of motion was encouraged immediately post-surgery. Patohistological examination of the specimen confirmed the diagnosis of paraarticular chondroma.

Keywords: paraarticular chondroma, carpal joint, pain, benign tumor

Introduction

Chondromas belong definitely among the most common forms of benign osseous tumors, estimated 20-50% of all benign bone tumors. These tumors mainly occur before the second decade of life, with a predisposition towards male individuals. Classically, these types of tumors are surface, osseous lesions, projecting from the underlying bone, composed of cortical and medullary components, accompanied by a hyaline cartilaginous cap^[1]. The radiographic features of cortical and medullary continuity with the underlying parent bone are often a pathognomonic sign. Most occurrent sites commonly include the metaphysis and the meta-diaphysis of long bones, including the femur and the tibia, often growing away from the articular surfaces. Symptoms are often derived from secondary fractures, formation of a bursa and irritation, neurological symptoms, joint involvement and rarely night pain due to malignant transformation^[2].

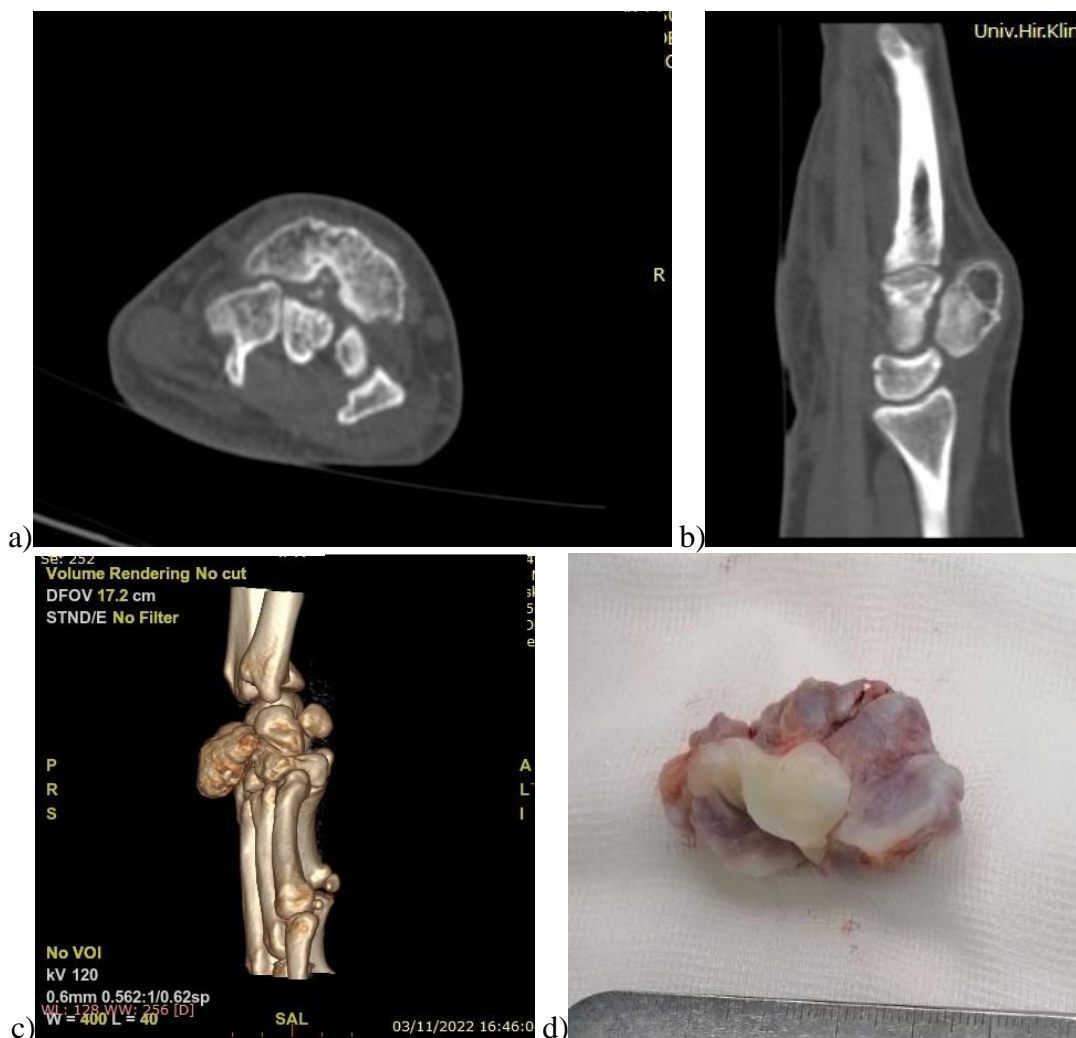


Fig. 1. (a, b) CT scan of the right wrist. Axial and sagittal plane, revealing the presence of paraarticular chondroma, invading the carpal bones. c) CT 3D reconstruction of the wrist. d) Gross pathology of the removed tumor.

Case report

We present a case of a 27-year-old male, who had a solid formation on his left wrist for approximately 10 years. He reported that in the last 4-5 years intermittent pain was present, tumefaction with a tendency of growth, and reduced range of motion. The tumefaction was located on the dorsal region of his left hand. He complained of pain, especially when he moved his fingers or during typing on a keyboard. On clinical examination, a 4 x 5 x 2 cm tumefaction on the dorsal region of the left wrist was noted. On palpation, the tumefaction was solid and fixed to carpal bones. Dorsal flexion on the left hand was reduced to 40 degrees compared to his right wrist. X-ray and CT scan were made. X-ray showed the presence of a small cartilaginous tumor, showing the actual involvement of the wrist in the vicinity of the carpal joints. The subsequent CT scan confirmed the more accurate margins of the tumor mass, showing how the chondroma expanded dorsally and proximally, reducing and invading the carpal space. An excisional biopsy was done. The histologic examination revealed a mature hyaline cartilage, with extensive ossification consistent with the diagnosis of extraskeletal chondroma.

Discussion

Chondromas are the most common benign bone tumors, occurring around the growth plates of long bones, especially in the skeletally immature population, and tend to extend into the diaphysis. Most common locations include the distal femur, proximal tibia, and humerus. Thus, an extra-articular chondroma in an adult is quite rare^[3]. In 1891, Virchow *et al.* hypothesized that a chondroma is derived from aberrant cartilaginous tissue, arising from the physis, separates during growth and gives rise to a separate area of bone formation through endochondral ossification^[4]. While extra-articular chondromas are usually asymptomatic, intra-articular variants cause pain and limitations in the range of motion of the affected joint. Eventually, the term para-articular chondromas was established to distinguish the latter from synovial chondromatosis^[5].

Several cases of para-articular chondromas of the wrist joint have been reported in the literature. Morin *et al.* reported a case of a 14-year-old girl who presented with progressive contracture of the left wrist joint^[6]. Although initially diagnosed as posttraumatic flexion contracture, computed tomography (CT) of the wrist showed increased bone density arising from the distal radius. The golden standard for diagnosis of an extra-articular chondroma is always a confirmation by histological examination. Shariatzadeh *et al.* similarly reported a case of a 33-year-old woman who presented with limitation of motion and pain in her right wrist for three years. Radiographic studies showed a bony mass in the anterior aspect of the distal radius with a calcified cortical margin. Although there are reports of arthroscopic excision being performed, open surgical exploration and careful excision remain the gold standard for treatment^[7]. In differential diagnosis we may consider: hematoma, synovial sarcoma, synovial chondrosarcoma, periosteal chondroma and bursitis. Treatment is surgical, with careful surgical excision to avoid injure of joint integrity^[8].

Conclusion

Many other entities are to be considered in the differential diagnosis of paraarticular chondromas, due to the similarities in the pathohistological and radiographic findings. Surgical excision represents a gold standard for the treatment of paraarticular chondromas. A careful and radical excision is crucial, to avoid tumor recurrence and injuries of the joint integrity and soft tissues.

Conflict of interest statement. None declared.

References

1. Peterson HA. Multiple hereditary chondromata. *Clin Orthop Relat Res* 1989; 239: 222-230. PMID: 2783565.
2. Sansón-RíoFrío JA, Navarro SS, Bahena RI, Villavicencio VV, Martínez-Said H, Padilla RA, *et al.* Differential diagnosis of multiple hereditary exostosis: presentation of a clinical case with secondary chondrosarcoma and literature review. *Acta Ortop Mex* 2009; 23(6): 376-382. PMID: 20377004.
3. Gaulke R. The distribution of solitary enchondromata at the hand. *J Hand Surg B*. 2002; 27(5): 444-445. doi: 10.1054/jhsb.2002.0826.
4. Harris NJ, Bell MJ. Bilateral scaphoid exostoses. *J Hand Surg Br* 1995; 20(6): 745. doi: 10.1016/s0266-7681(95)80039-5.
5. van Alphen JC, te Slaa RL, Eulderink F, Obermann WR. Solitary osteochondroma of the scaphoid: a case report. *J Hand Surg Am* 1996; 21(3): 423-425. doi: 10.1016/S0363-5023(96)80356-X.

6. Spinner RJ, Spinner M. Superficial radial nerve compression due to a scaphoid exostosis. *J Hand Surg Br* 1996; 21(6): 781-782. doi: 10.1016/s0266-7681(96)80189-6.
7. Hofmann AK, Wüstner MC, Spier W. Compression neuropathy of the median nerve at the wrist joint caused by chondroma. *Handchir Mikrochir Plast Chir* 1990; 22(2): 96-98. PMID: 2186986.
8. Samardziski M, Foteva M, Adamov A, Zafiroski G. Intracapsular and para- articular chondroma of knee: a report of four cases and review of the literature. *Radiology Oncology* 2006; 40 (4): 205-209.