

## DISC HERNIATIONS AND NEURAL STRUCTURES COMPRESSION IN DIFFERENT LUMBOSACRAL TRANSITIONAL ANATOMY TYPES

Matveeva Niki<sup>1</sup>, Chabukovska Radulovska Jasmina<sup>2</sup>, Petrovska Tanja<sup>2</sup>, Zhivadinovik Julija<sup>1</sup>, Zafirova Biljana<sup>1</sup>

<sup>1</sup>Institute of Anatomy, Faculty of Medicine,

<sup>2</sup>University Clinic for Surgery “St. Naum Ohridski” Skopje,  
Ss. Cyril and Methodius University Skopje, R.N. Macedonia  
e-mail: niki.matveeva@medf.ukim.edu.mk

### Abstract

**Introduction.** Several studies describe the relationship between different lumbosacral transitional vertebra (LSTV) types, disc herniations and neural structures compression in the central and nerve root canal.

The objective of this study was to evaluate the relationship between different LSTV groups and disc herniations associated with the grade of neural structures compression in the central and nerve root canal at transitional and at adjacent proximal to LSTV level.

**Material and methods.** A total of 145 patients with lumbosacral radicular syndrome who underwent MRI examination of the lumbar spine were retrospectively analyzed. The study group comprised 75 patients who presented with LSTV, divided into four subgroups based on Castellvi classification. Seventy patients without LSTV were assigned to the control group.

**Results.** There were significantly more disc herniations at the L/S junction in the study LSTV group compared to the control group (78.7 % vs 59.4%,  $p=.012$ ). In the LSTV group more severe cauda equina and bilateral subarticular nerve root compression at the L/S junction was found (9%,  $p=.002$ ) compared to the control group. Among the LSTV subgroups, more cauda equina compression was observed mainly in bilateral osseous and bilateral combined fusion group (57%, 54% vs 26%;  $p=.009$ ,  $p=.012$ ). At the adjacent proximal level severe cauda equina compression was significantly increased in the LSTV compared to the control group (34.7% vs 21.4%;  $p=.038$ ). Among the LSTV subgroups severe cauda equina compression was most prevalent in bilateral articular fusion subgroup (42% vs 21%;  $p=.028$ ).

**Conclusion.** LSTV restrict the spinal segment mobility and transfer the external stress factors to the ipsilateral anomalous articulation, to the contralateral facet joint at the level of unilateral transition and to the spine fully mobile segments proximal to bilateral osseous or articulated fusion. These levels become high stress zones predisposing the occurrence of massive, large disc herniations associated with severe neural structures compression.

**Key words:** lumbosacral transitional vertebra, MRI, disc herniation, cauda equine, nerves, spinal

## Introduction

Lumbosacral transitional vertebra (LSTV) is congenital developmental spinal anomaly of the lumbosacral junction of the spine. Definite alterations of this anomaly are lumbarisation of the first sacral segment with non-fusion between the first two sacral segments and sacralisation of the fifth lumbar vertebra with fusion (osseus or articular) between L5 and the first sacral segment. These alterations can be classified using the Castellvi classification into four different groups<sup>1</sup>. The incidence of LSTV is between 7 and 36% in the general population<sup>2-6</sup>. Controversial opinions are reported regarding the clinical significance of this entity and its association with low back pain. It has been accepted that the presence of LSTV may affect the incidence and the level of herniation of the lumbar discs. Many authors have found a significant difference in the distribution of bulging discs and disc herniations between patients with LSTV and normal lumbosacral junction<sup>7</sup>. Some authors have noticed that this developmental anomaly leads to earlier occurrence and more severe disc degenerative changes and disc herniations in younger individuals<sup>8-9</sup>. However, many authors demonstrated that there was also an increase in the degenerative changes such as disc degeneration, facet degeneration, central canal and nerve root canal stenosis just above the transitional lumbosacral segments. In accordance with this opinion, authors reported that LSTV is protective for disc degeneration at the transitional segment, but predispose to greater disc degeneration at the level above<sup>10,11</sup>. There is still a small number of studies that investigate the association between different LSTV groups and disc herniations at the level of transition and at the adjacent proximal to LSTV level. Since disc herniations are the most frequent cause of neural structures compression, besides surrounding osseus, ligamentous and articular structures the investigation of the association of LSTV with neural structures compression can provide a deeper insight in the development of disc herniations under conditions of altered morphology and biomechanics in LSTV.

The objective of this study was to evaluate the relationship between different LSTV groups and disc herniations (in terms of their prevalence, morphology and distribution) associated with the grade of neural structures compression in the central and nerve root canal at the transitional level and at the adjacent proximal to LSTV level. These findings can help the clinicians to make a decision for the treatment or surgeons to select appropriate fusion or disc replacement level in patients with different LSTV types.

## Material and methods

### Subjects

Our study was a part of the scientific project registered and approved by the Institutional review board at the Faculty of Medicine with the collaboration of the University Clinic for Surgery "St. Naum Ohridski" at Ss. Cyril and Methodius University in Skopje. In our study, MRI examinations of the lumbar spine performed from September 2016 to October 2017 in patients referred by their general practitioner with lumbosacral radicular syndrome were retrospectively analyzed. According to the national general practitioner guideline, patients with diagnosis of lumbosacral radicular syndrome confirmed by a neurologist, after unsuccessful conservative treatment for at least six weeks were subject to MRI examination of the lumbar spine. After Institutional review board approval, 75 patients (41 males, 34 females, mean age 55.54±9 years) who presented with LSTV were retrospectively selected and included in the study. This group was divided into four subgroups based on the Castellvi classification - unilateral articular fusion group (N=20); bilateral articular fusion group (N=26); bilateral osseus fusion group (N=14) and combined bilateral fusion group (N=15). These patients were referred to as the study group. Seventy patients (36 males, 34 females, mean age 56.6 ±10 years) without LSTV were added randomly and referred to as the control

group. Patients with kyphoscoliosis, spondylolisthesis, history of previous spine surgery, spinal fracture, other congenital spinal anomalies, tumor or infection were excluded from the study.

#### MR images

All patients underwent the same imaging protocol. MR imaging examination of the lumbosacral spine was performed with 1.5 T MR unit (Signa HDI) with a spinal surface coil. The imaging protocol consisted of sagittal T1-weighted fast spin-echo sequence (FSE) (repetition time msec/echo time msec, 800/14; section thickness, 4 mm; field of view, 360x360 mm; matrix, 448 x 224), sagittal T2-weighted turbo spin-echo sequence (3520/102; section thickness, 4 mm; intersection gap, 10 mm; echo train length of 24, coronal T2-weighted FSE and axial T2-weighted FSE sequences at one or multiple levels (4,660/120; section thickness, 4 mm; intersection gap, 0.6 mm; echo train length of 27; field of view, 200x200 mm; matrix 320 x 256) and oblique HI RES T2 FRFSE (fast relaxation fast spin echo), (TR/TE 3000/88; section thickness 2 mm, intersection gap 1 mm; field of view 22x22, matrix 320x320).

All images were reviewed by two experienced diagnostic radiologists blinded to the original reports of the MRI studies. The Kappa value for the inter-observer result was 0.82 (range, 0.81-0.93) indicating substantial perfect agreement.

The L5/S1 and L4/5 level in subjects without LSTV and the L/S junction (at the level of transition in articular fusion LSTV groups; proximal to the level of transition in osseous and combined fusion LSTV groups) and the adjacent proximal level in subjects with LSTV were observed and assessed for the presence of disc herniations, their type and anatomic localization and the grade of neural structures compression in the central and nerve root canal due to the displaced disc material. Disc contour was assessed using the recommendations of the Combined Task Forces of NASS, ASSR, and ASNR<sup>12</sup>. Herniated discs were classified as protrusion or extrusion, based on the shape of the displaced material and sequestration (lost continuity with the parent disc). Bulging discs (disc tissue extending beyond the edges of the apophyses), symmetric and asymmetric were not considered a form of herniation, but were evaluated because of their potential to cause significant compression of the neural structures. The anatomic location of the herniations in the transverse plane was defined by the boundaries of the central, subarticular, foraminal and extraforaminal zone<sup>13</sup>. Neural structures compression was assessed in subjects with disc herniations and disc bulgings. Cauda equina compression was graded with a system based on the obliteration of the anterior CSF space and separation degree of the cauda equina on T2 weighted axial images - no compromise of the dural sac without obliteration of anterior CSF space; mild stenosis with separation of all cauda equina; moderate stenosis with some cauda equina aggregated; severe stenosis with none of cauda equina separated<sup>14</sup>. Nerve root compromise due to the displaced disc material in the subarticular zone was evaluated with Phirrmann grading system - no compromise; contact of the disc material with the nerve root; deviation of nerve root and compression of nerve root<sup>15</sup>. Nerve root impingement in the foraminal zone was assessed through the amount of perineural intraforaminal fat - no foraminal stenosis; stenosis with obliteration of perineural fat in opposite directions, vertical or transverse; perineural fat obliteration in both directions or nerve root collapse<sup>16</sup>.

Statistical analysis was performed using the SPSS (version 20, Chicago, IL, USA). A chi-square test was used for statistical comparison between the LSTV groups and the control group for disc herniations and disc bulgings. To compare the grades of central and nerve root canal stenosis an unpaired, two tailed Mann Whitney test was used. A p value less than 0.05 was considered statistically significant.

## Results

### Disc herniations

There were significantly more disc herniations in the study LSTV group at the L/S junction compared to the control group at the L5-S1 level (78.7 % vs 59.4%;  $p=0.012$ ) (Table 1).

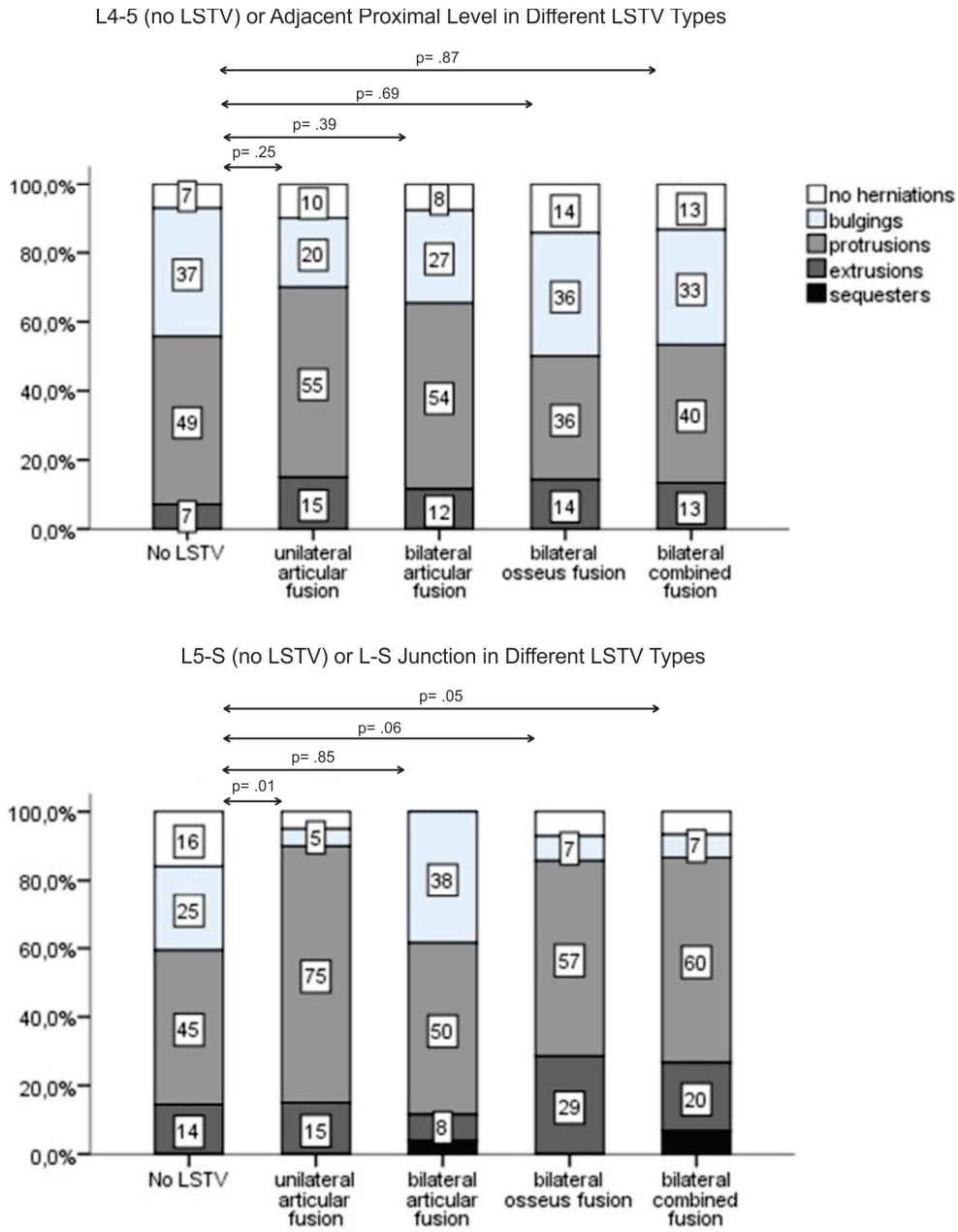
**Table1.** Comparison of disc herniations and severe neural structures compression between the control group (no LSTV) and the study group (with LSTV)

L4/5 in the control group or adjacent proximal level to the level of transition in LSTV group	Control group	LSTV group	P value
Disc herniations	39 (55.7%)	46 (61.3%)	0.492
Disc bulgings	26 (37%)	21 (28%)	0.443
Severe cauda equina compression	15 (21.4%)	26 (34.7%)	0.038
Bilateral subarticular nerve root compression	14 (20%)	20 (26.7%)	0.137
Bilateral foraminal circumferential nerve root compression	5 (7%)	15 (20%)	0.000
L5-S1 in the control group or L-S junction in LSTV group	Control group	LSTV group	P value
Disc herniations	41 (59.4%)	59 (78.7%)	0.012
Disc bulgings	17 (24.6%)	13 (17.3%)	0.017
Severe cauda equina compression	/	7 (9.3%)	0.002
Bilateral subarticular nerve roots compression	/	7 (9.14%)	0.000
Bilateral foraminal circumferential nerve root compression	9 (12.9%)	14 (18.7%)	0.083

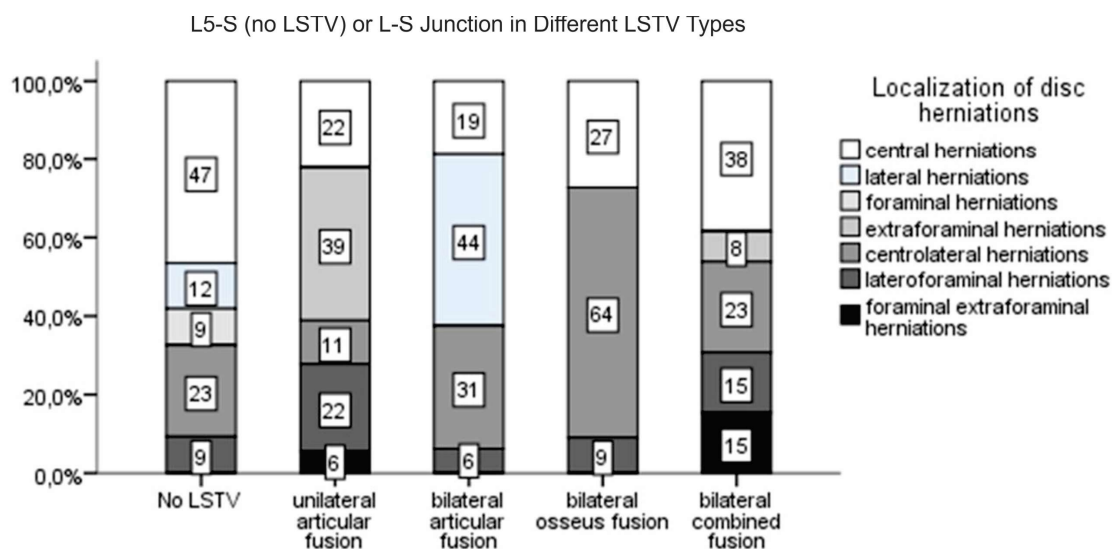
LSTV, lumbosacral transitional vertebra

The increased number of disc herniations was observed particularly for unilateral articular fusion, bilateral osseus and bilateral combined fusion LSTV groups, each one compared with the control group (90%, 86%, 87% vs 59%;  $p=0.011$ ,  $p=0.062$ ,  $p=0.046$ ) (Fig. 1). Extraforaminal disc herniations were a common finding for unilateral articular fusion subgroup (39%) (Fig. 2). Disc herniations with wider base of origin were more frequently observed in bilateral osseus and bilateral combined fusion subgroup (73%, 53%) (Fig. 2).

At the adjacent proximal level in the study LSTV group more disc herniations compared to the control group were evaluated (61.3% vs 55.7%;  $p=0.492$ ) (Table 1). The same finding was observed for unilateral and bilateral articular fusion groups, each one compared with the control group (70%, 66% vs 56%;  $p=0.25$ ,  $p=0.39$ ) (Fig. 1). At this level less disc herniations compared to the control group were notified in osseus fusion and combined fusion subgroup (50%, 53%) (Fig. 1).



**Fig. 1.** Prevalence of different types of disc herniations in the control group (no LSTV) and in the different LSTV groups (unilateral articular fusion, bilateral articular fusion, bilateral osseus fusion and combined fusion groups) at L5/S1 or L/S level and at L4/L5 or the adjacent proximal level



**Fig. 2.** Localization of disc herniations in the control group (no LSTV) and in the different LSTV groups (unilateral articular fusion, bilateral articular fusion, bilateral osseus fusion and combined fusion groups) at L5/S1 or L/S level

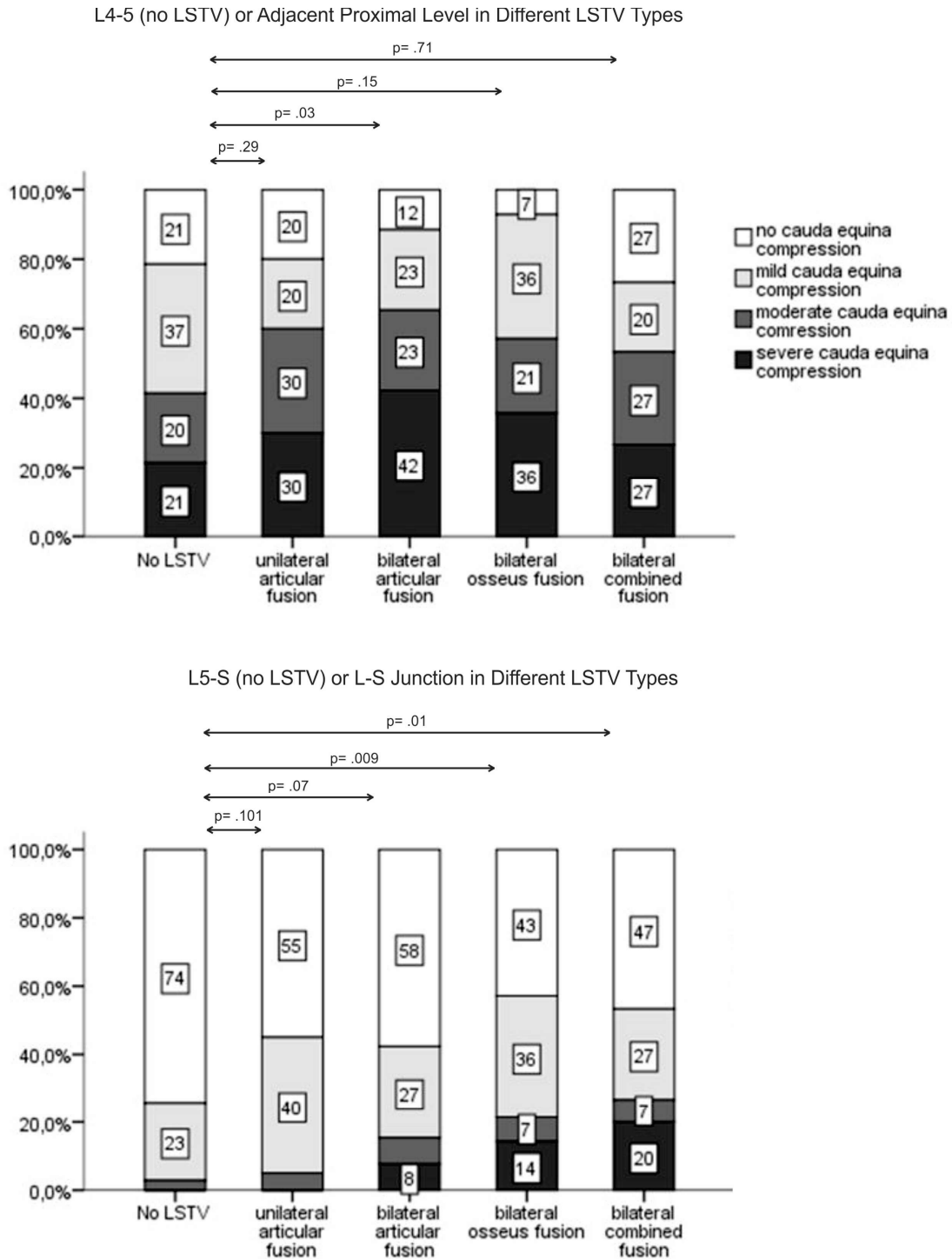
#### *Neural structures compression*

Assessment of the neural structures compression in the central and nerve root canals in order to qualify substantial displacement of the disc material was made in patients with disc herniations and disc bulgings.

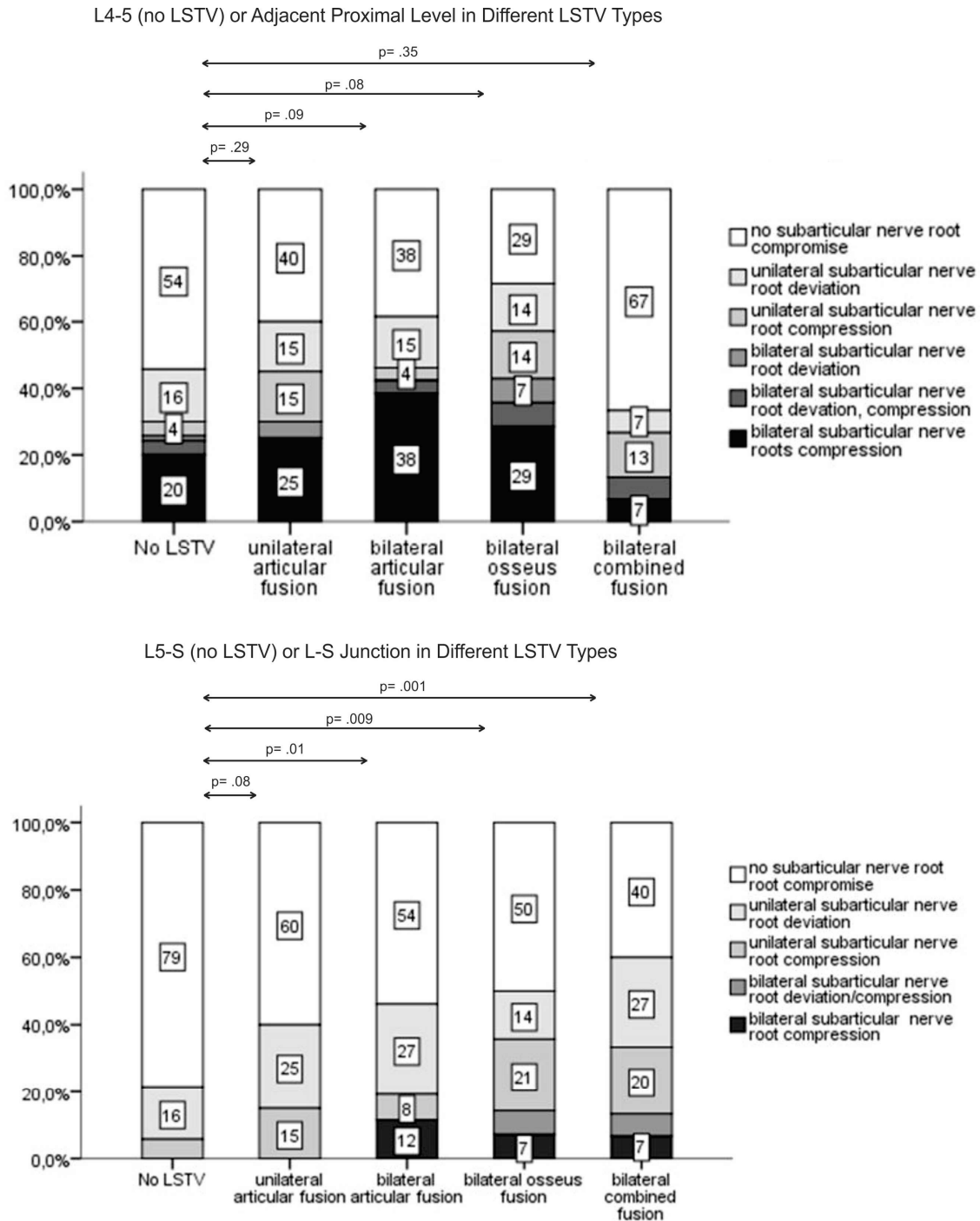
At L5/S1 level in the control group no severe cauda equina and bilateral subarticular nerve root compression was observed. In the LSTV group severe cauda equina and bilateral subarticular nerve root compression at the L/S junction was notified in 7 subjects (9.3%, 9.14%;  $p=.002$ ,  $p=.000$ ) (Table 1). Among the LSTV groups, cauda equina compression due to massive disc herniations was observed mainly in bilateral osseus and bilateral combined fusion group (57%, 54% vs 26%;  $p=.009$ ,  $p=.012$ ) (Fig. 3). A significantly more subarticular nerve root compression among the LSTV groups was found in bilateral articular, bilateral osseus and bilateral combined fusion subgroup (47%, 50%, 60% vs 21%;  $p=.011$ ,  $p=.009$ ,  $p=.001$ ; Fig. 4). At the lumbosacral junction bilateral circumferential foraminal nerve root compression was more frequent finding in the LSTV group compared to the control group (18.7% vs 13%;  $p=.083$ ) (Table 1). Among the LSTV groups more foraminal nerve root compression was observed in the osseus and combined fusion group (50%, 60% vs 27%;  $p=.112$ ,  $p=.011$ ) (Fig. 5). High prevalence of unilateral nerve root compression was notified in unilateral articular fusion and combined fusion group (15%, 33%) (Fig. 5).

At the adjacent proximal level severe cauda equina compression was significantly increased in the LSTV group (34.7% vs 21.4%;  $p=.038$ ) (Table 1). Among the LSTV groups cauda equina compression was most prevalent in bilateral articular fusion subgroup (88%;  $p=.028$ ) (Fig. 3). At the adjacent proximal level severe bilateral subarticular nerve root compression was more frequent finding in the LSTV group compared to the control group (26.7% vs 20%;  $p=.137$ ) (Table 1). Among the LSTV groups the most subarticular nerve root compression was found in bilateral articular and bilateral osseus fusion subgroup (62%, 71% vs 46%;  $p=.092$ ,  $p=.085$ ) (Figure 4).





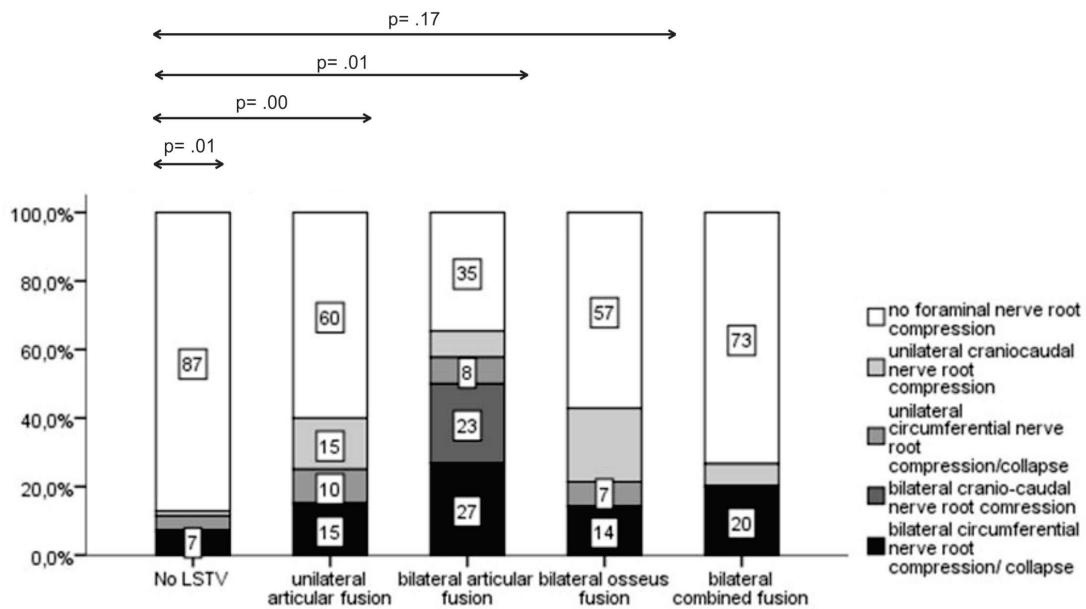
**Fig. 3.** Grades of cauda equina compression in the control group (no LSTV) and in the different LSTV groups (unilateral articular fusion, bilateral articular fusion, bilateral osseus fusion and combined fusion groups) at L5/S1 or L/S level and at L4/L5 or the adjacent proximal level



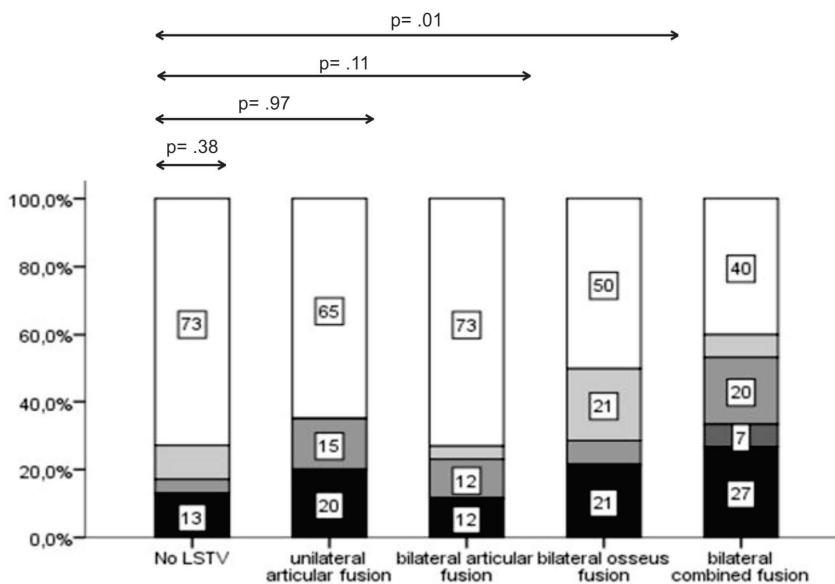
**Fig. 4.** Subarticular nerve root compression in the control group (no LSTV) and in the different LSTV groups (unilateral articular fusion, bilateral articular fusion, bilateral osseus fusion and combined fusion groups) at L5/S1 or L/S level and at L4/L5 or the adjacent proximal level



L4-5 (no LSTV) or Adjacent Proximal Level in Different LSTV Types



L5-S (no LSTV) or L-S Junction in Different LSTV Types



**Fig. 5.** Foraminial nerve root compression in the control group (no LSTV) and in the different LSTV groups (unilateral articular fusion, bilateral articular fusion, bilateral osseus fusion and combined fusion groups) at L5/S1 or L/S level and at L4/L5 or the adjacent proximal level

At the adjacent proximal level significantly more severe bilateral circumferential nerve roots compression was observed in the LSTV group (20% vs 7%;  $p = .000$ ) (Table 1). In bilateral articular group the most foraminial nerve root compression was notified (65%;  $p = .000$ ). In the combined fusion and bilateral articular fusion group the most severe bilateral circumferential foraminial nerve root compression was observed (27%, 20% vs 7%) (Fig. 5).

The most frequent unilateral foraminal nerve root compression was notified in unilateral articular fusion subgroup (25%) (Fig. 5).

### Discussion

The potential association between an LSTV and low back pain is controversial and has been supported or disputed since it was first described by Bertolotti in 1917<sup>17</sup>. The exact etiology of Bertolotti's syndrome remains unclear. The low back pain of this syndrome is currently reported to be of varying etiologies arising from different locations like disc degenerative changes or disc herniations, spinal canal stenotic changes as a consequence of a disc pathology or posterior elements pathology (facet joint arthrosis) at the level above an LSTV. At the level of LSTV the low back pain can be related to a degeneration of the anomalous articulation between the LSTV and the sacrum, facet joint arthrosis contralateral to the unilateral articulated fusion or extraforaminal stenosis secondary to the presence of a broadened transverse process<sup>18,19</sup>.

In the literature, the reported prevalence of LSTV in patients being imaged for low back pain or surgery for disk pathology is greater than expected. It has been reported that the Bertolotti's syndrome in the under-30 age group was seen to be present in nearly one in five patients, a much higher incidence than previously identified<sup>20</sup>. According to Paik et al. among 8,280 patients with low back pain, 10.6% had LSTV<sup>21</sup>. Avimadje et al. found 52.7% of patients with a lumbar disc herniation who also had an LSTV, while only 18.3% of the control group had an LSTV<sup>22</sup>. Our findings showed that among the adult population with lumbosacral radicular syndrome there was a higher prevalence of disc herniations in patients with LSTV compared to the control group, at the level of lumbosacral junction (79% vs 59%) and at the adjacent proximal level (61% vs 56%). According to Otani *et al.*<sup>7</sup> patients with transitional vertebra experienced disc herniation more frequently (17% vs 11%) and at a younger age (35 years old vs 59 years old) compared to patients without a transitional vertebra. Our results showed that higher prevalence of disc herniations at the lumbosacral junction was found predominantly in unilateral articular, bilateral osseus and combined fusion LSTV groups compared to the control group. The osseous bridging at the transitional level results in complete lack of movements at the level of fusion, incorporate the lumbar vertebra into the sacral mass and preserve the disc from degeneration. Newly formed lumbosacral junction is the last fully mobile level, affected by hypermobility and abnormal torque movements that predispose disc herniations to occur more frequently at L/S junction. Severe cauda equina and subarticular nerve root compression at the L/S junction in transitional states was seldom evaluated, mainly as a consequence of massive herniations in osseus and combined fusion LSTV groups. The effect of osseously fused vertebra on the adjacent proximal disc may correlate with the situation after a fusion operation when the movement at one or more disc spaces (fusion levels) is restricted in relation to other disc levels (proximal to the fusion levels). Aihara *et al.* found that the iliolumbar ligaments above an LSTV were thinner and weaker, predisposing this level to hypermobility<sup>23</sup>. According to our data, lumbar disc herniations occurred more frequently on the side of articular fusion in unilateral articular fusion in contrast to the biarticular fusion group where disc herniations were more frequent finding at the level above the bilateral articular fusion. Unilateral articular fusion results in asymmetric morphology and biomechanic alterations. The side bearing the additional pseudoarticulation supports a larger proportion of load, increases one-sided muscle activity resulting in asymmetrical and unbalanced movement, factors that influence on the onset of disc herniations on the side of the anomalous articulation. Most of the herniations in unilateral articular fusion group were foraminal and extraforaminal. It has been reported that extraforaminal stenosis leads to nerve root entrapment and radiculopathy in patients with an LSTV. Nerve root compression in unilateral articular fusion group can be

a consequence of pinching the root between the broadened transverse process of the 5th lumbar vertebra and the sacral ala, a condition known as "Far-Out Syndrome". Asymmetry can also cause early degenerative changes within the normal contralateral facet joint, giving rise to facet pain<sup>24-27</sup>. Many authors described successful treatment of contralateral facetogenic pain by resection of the anomalous transverse process with the accompanying pseudoarticulation<sup>28</sup>.

Otani *et al.*<sup>7</sup> found 83% of patients with a disc herniation in the presence of an LSTV experienced symptoms arising from the last caudal mobile segment. According to our data at the adjacent proximal level, disc herniations with severe neural structures compromise were most prevalent in bilateral articular fusion group. Bilateral articular fusion leads to balanced reduced mobility of the lumbosacral junction and transfers stress to the adjacent proximal mobile segment. Bilateral osseous or combined fusion completely restrict mobility at the level of fusion and transfer the stress to the level that assumes the role of lumbosacral junction. Therefore, in our study more massive disc herniations associated with severe neural structures compression were found at the adjacent proximal level in bilateral articular fusion group and both at L/S level and at the adjacent proximal level in bilateral osseous and combined fusion groups. This finding confirms the thesis of more excessive transfer of stress from the segments with restricted mobility to the spine fully mobile segments. Many authors suggest that low back pain might be worse in the presence of an LSTV. Among 881 young male patients, Taskaynatan *et al.*<sup>29</sup> reported that the presence of an LSTV increased the severity of patient's clinical picture and severity of pain. Yavuz *et al.*<sup>30</sup> described that subjects with low back pain and no malformation reported an average pain level on the Visual Analog Scale for Pain (VAS) of 2.2 versus 4.8 in patients with low back pain and a transitional vertebra. Secer *et al.*<sup>31</sup> found an occurrence rate of 4.5% LSTV in young subjects with neurologic deficit and low back pain. More frequent occurrence of severe neural structures compression in LSTV found in our study is consistent with these findings. Severe radiating pain in patients with an LSTV can be a consequence of increased prevalence of massive disc herniations associated with severe neural structures compression in the central and nerve root canal at the high stress levels.

Assessment of spinal segmentation before surgery is very important in order to eliminate surgical and procedural errors. Most wrong-level spine surgery occurs in patients with spinal anatomy variations, including LSTV<sup>32</sup>. Surgeons should also take into consideration altered morphology and biomechanics in transitional states especially when they decide on selection the adequate level for total disc replacement, levels of fusion or in application of adequate fusion technique. Farshad-Amacker *et al.* investigated disc degeneration in different LSTV types and found that the increase of mechanical connection in LSTV protected the disc, but predisposed the adjacent proximal segment to greater degeneration<sup>33</sup>.

Limitations of our study may be the patients included in the control and study group who did not belong to asymptomatic population and the small sample of LSTV groups. However, our findings are not a result of selection bias and were verified by the comparison between the LSTV group and the control group.

### **Conclusion**

In conclusion, altered morphology of the lumbosacral junction in LSTV restrict the spinal segment mobility resulting in altered biomechanics and transfer the external stress factors to the ipsilateral anomalous articulation, to the contralateral facet joint at the level of unilateral transition and to the spine fully mobile segments proximal to bilateral articulated or osseous fusion. These levels become high stress zones that predispose the occurrence of

massive, large disc herniations associated with severe neural structures compression in the central and nerve root canals.

### References

1. Castellvi AE, Goldstein LA, Chan DP. Lumbosacral transitional vertebra and their relationship with lumbar extradural defects. *Spine* (Phila Pa 1976). 1984; 9: 493-495.
2. Apazidis A, Ricart PA, Diefenbach CM, Spivak JM. The prevalence of transitional vertebrae in the lumbar spine. *The Spine Journal:official journal of the North American Spine Society* 2011; 11(9): 858-862.
3. Nardo L, Alizai H, Virayavanich W, Liu F, Hernandez A, Lynch JA, et al. Lumbosacral transitional vertebrae: association with low back pain. *Radiology* 2012; 265: 497-503.
4. Quinloye OI, Abdulkadir AY, Babalola OM. Incidence and patterns of lumbosacral transitional vertebra in patients with low back pain in a Nigerian hospital. *Nig Q J Hosp Med* 2009; 19:95-99.
5. Delpont EG, Cucuzzella TR, Kim N, Marley J, Pruitt C, Delpont AG. Lumbosacral transitional vertebra: incidence in a consecutive patients series. *Pain Physician* 2006;9:53-56.
6. Hsieh CY, Vanderford JD, Moreau SR, Prong T. Lumbosacral transitional segments: classification, prevalence, and effect on disk height. *J Manipulative Physiol Ther* 2000; 23: 483-489.
7. Otani K, Konno S, Kikuchi S. Lumbosacral transitional vertebrae and nerve-root symptoms. *J Bone Joint Surg [Br]*. 2001; 83-B: 1137-1140.
8. Zhang B, Wang L, Wang H, Guo Q, Lu X, Chen D. Lumbosacral Transitional Vertebra: Possible Role in the Pathogenesis of Adolescent Lumbar Disc Herniation. *World Neurosurg* 2017;107:983-989. doi: 10.1016/j.wneu.2017.07.095. Epub 2017 Jul 24. PMID: 28751140.
9. Bron JL, van Royen BJ, Wuisman PI. The clinical significance of lumbosacral transitional anomalies. *Acta Orthop Belg* 2007;73: 687-695.
10. Luoma K, Vehmas T, Raininko R, Luukkonen R, Riihimäki H. Lumbosacral transitional vertebra: relation to disc degeneration and low back pain. *Spine* 2004; 29: 200-205.
11. Aihara T, Takahashi K, Ogasawara A, Itadera E, Ono Y, Moriya H. Intervertebral disc degeneration associated with lumbosacral transitional vertebrae: a clinical and anatomical study. *J Bone Joint Surg [Br]* 2005; 87: 687-691.
12. Fardon FD, Williams LA, Dohring JE, Murtagh R, Rothman SLG, Sze GK. Lumbar disc nomenclature: version 2.0. Recommendations of the combined task forces of the North American Spine Society, the American Society of Spine Radiology and the American Society of Neuroradiology. *The Spine Journal* 2014; 14: 2525-2545.
13. Wiltse LL, Berger PE, McCulloch JA. A system for reporting the size and location of lesions in the spine. *Spine* 1997; 22: 1534-1537.
14. Lee GY, Lee JW, Choi HS, Oh KJ, Kang HS. A new grading system of lumbar central canal stenosis on MRI: an easy and reliable method. *Skeletal Radiol* 2011; 40(8): 1033-1039.
15. Phirmann CWA, Dora C, Schmid MR, Hodler J, Boos N. MR image-based Grading of Lumbar Nerve Root Compromise due to Disc Herniation: Realibility Study with Surgical Correlation. *Radiology* 2004; 230: 583-588.
16. Lee S, Lee JW, Yeom JS, Kim KJ, Kim HJ, Chung SK, Kang HS. A practical MRI grading system for lumbar foraminal stenosis. *AJR* 2010; 194: 1095-1098.

17. Konin GP, Walz DM. Lumbosacral transitional vertebrae: classification, imaging findings, and clinical relevance. *Am J Neuroradiol* 2010; 31: 1778-1786.
18. Albert HB, Briggs AM, Kent P, Byrhagen A, Hansen C, Kjaergaard K. The prevalence of MRI-defined spinal pathoanatomies and their association with Modic changes in individuals seeking care for low back pain. *Eur Spine* 2011; 20: 1335-1362.
19. Brault JS, Smith J, Currier BL. Partial lumbosacral transitional vertebra resection for contralateral facetogenic pain. *Spine (Phila Pa 1976)* 2001;26:226–229
20. Quinlan JF, Duke D, Eustace S. Bertolotti's syndrome: a cause of back pain in young people. *J Bone Joint Surg [Br]* 2006; 88: 1183-1186.
21. Paik NC, Lim CS, Jang HS. Numeric and morphological verification of lumbosacral segments in 8280 consecutive patients. *Spine* 2013; 38(10): E573-578.
22. Avimadje M, Goupille P, Jeannou J, Gouthiere C, Valat JP. Can an anomalous lumbosacral or lumbo-iliac articulation cause low back pain? A retrospective study of 12 cases. *Revue du rhumatisme (English ed)*. 1999; 66(1): 3539.
23. Aihara T, Takahashi K, Ogasawara A, Itadera E, Ono Y, Moriya H. Intervertebral disc degeneration associated with lumbosacral transitional vertebrae: a clinical and anatomical study. *J Bone Joint Surg Br* 2005;87:687–691.
24. Weber J, Ernestus RI. Transitional lumbosacral segment with unilateral transverse process anomaly (Castellvi type 2A) resulting in extraforaminal impingement of the spinal nerve: a pathoanatomical study of four specimens and report of two clinical cases. *Neurosurgical review* 2010; 34(2): 143-150.
25. Abe E, Sato K, Shimada Y, Okada K, Yan K, Mizutani Y. Anterior decompression of foraminal stenosis below a lumbosacral transitional vertebra. A case report. *Spine* 1997; 22(7): 823-826.
26. Ichihara K, Taguchi T, Hashida T, Ochi Y, Murakami T, Kawai S. The treatment of far-out foraminal stenosis below a lumbosacral transitional vertebra: a report of two cases. *Journal of spinal disorders & techniques*. 2004; 17(2): 154-157.
27. Porter NA, Lalam RK, Tins BJ, Tyrrell PN, Singh J, Cassar-Pullicino VN. Prevalence of extraforaminal nerve root compression below lumbosacral transitional vertebrae. *Skeletal radiology*. 2014; 43(1): 55-60.
28. Ugokwe KT, Chen TL, Klineberg E. Minimally invasive surgical treatment of Bertolotti's syndrome: case report. *Neurosurgery* 2008;62:454–455
29. Taskaynatan MA, Izi Y, Ozgul A, Hazneci B, Dursun H, Kalyon TA. Clinical significance of congenital lumbosacral malformations in young male population with prolonged low back pain. *Spine* 2005; 30(8): E210-213.
30. Yavuz U, Bayhan AI, Beng K, Emrem K, Uzun M. Low back complaints worse, but not more frequent in subjects with congenital lumbosacral malformations: a study on 5000 recruits. *Acta orthop Belg* 2012; 78(5): 668-671.
31. Secer M, Muradov JM, Dalgic A. Evaluation of congenital lumbosacral malformations and neurological findings in patients with low back pain. *Turkish neurosurgery* 2009; 19(2): 145-148.
32. Hughes RJ, Saifuddin A. Numbering of lumbosacral transitional vertebrae on MRI: role of the iliolumbar ligaments. *AJR Am J Roentgenol* 2006;187:W59–W65.
33. Farshad Amacker NA, Herzog RJ, Hughes AP, Aichmair A, Farshad M. Associations between lumbosacral transitory anatomy types and degeneration at the transitional and adjacent segments. *The Spine Journal* 2015; 15: 1210-1216.