

Received: October 10, 2025
Accepted: November 11, 2025

Acad Med J 2025;5(3):216-221
UDC: 617.73/.75
<https://www.doi.org/10.53582/AMJ2553216t>
Case report

DIAGNOSTIC EVALUATION AND SURGICAL TREATMENT OF EXOTROPIA IN A PATIENT WITH STRAATSMA SYNDROME - CASE REPORT

Tateshi Bekim^{1,3}, Pandilov Stefan^{1,2}, Tateshi Velju Era^{3,4}

¹University Clinic for Eye Diseases, Skopje, Republic of North Macedonia,

²Faculty of Medicine, Ss. Cyril and Methodius University in Skopje, Republic of North Macedonia

³Faculty of Medical Sciences, "Goce Delchev" University in Shtip, Shtip, Republic of North Macedonia

⁴City General Hospital "8th September", Ophthalmology Department, Skopje, Republic of North Macedonia

e-mail: stefan.pandilov@gmail.com

Abstract

Straatsma syndrome is a rare ophthalmic condition characterized by the triad of myelinated retinal nerve fibers, high myopia, and amblyopia. It is often associated with strabismus, nystagmus, heterochromia of the iris, and optic nerve hypoplasia.

We present a case of a 22-year-old patient with this syndrome, who presented with high unilateral myopia, amblyopia, and myelinated retinal nerve fibers along the inferior temporal arcade of the affected eye. In addition, the patient had a hypoplastic optic nerve and a large-angle exotropia, which required surgical correction for cosmetic reasons. Due to untreated amblyopia in childhood, the patient had very poor visual function in the affected eye.

This case highlights the importance of early recognition and diagnosis of Straatsma syndrome, as delayed diagnosis may prevent effective treatment of amblyopia.

Keywords: amblyopia, myopia, myelinated retinal nerve fibers, Straatsma syndrome, strabismus

Introduction

Bradley R. Straatsma and his colleagues first described a series of four patients with unilateral myopia, amblyopia and strabismus associated with myelinated retinal nerve fibers (MRFL) in 1979^[1]. Later, the triad of myopia, amblyopia and MRFL was also observed by other authors, after which it was named Straatsma syndrome. In addition to this triad, patients with this syndrome often also have: strabismus, nystagmus, heterochromia of the iris and/or hypoplastic optic nerve^[2,3]. The presence of these additional entities does not change the diagnosis of Straatsma syndrome.

In recent decades, cases of bilateral Straatsma have been published, as well as cases in which, instead of myopia, hyperopia has been encountered, the so-called "reverse Straatsma syndrome"^[3,4].

The greatest challenge in these patients is the treatment of amblyopia, which can be quite severe. Risk factors associated with poorer visual acuity outcomes include high anisometropia, strabismus, extensive myelination, and macular involvement^[2,5]. According to Straatsma, the marked visual impairment, exotropia, and early onset of symptoms suggest that amblyopia is likely organically caused^[1].

In this paper, we describe a case of a patient in whom Straatsma syndrome was discovered during an ophthalmological examination for aesthetic management of exotropia.

Case report

A 22-year-old patient came to our clinic for an ophthalmological examination due to exotropia of the left eye and poor vision in the same eye since childhood. The best-corrected visual acuity of the right eye was 1.0 sc, and of the left eye 0.01 (-16.0 DSph, -4.50 DCyl Ax 142°). In the primary position, the left eye was in exotropia with an angle of 25°, i.e. 50Δ; the patient did not recognize any stereoscopic figure during the Lang test. Tonometry was bilaterally within reference values. Fundoscopically, the structures of the posterior segment of the right eye were normal, while in the left eye a tilted and hypoplastic optic nerve papilla was observed, a wide zone of myelinated retinal nerve fibers along the inferior temporal arcade, whose blood vessels were markedly tortuous. The presence of myelinated retinal nerve fibers, amblyopia, high axial myopia, supplemented by exotropia and hypoplasia of the optic nerve head were sufficient to establish a diagnosis of Straatsma syndrome. The patient was additionally subjected to fundus photography and optical coherence tomography in order to document the changes in the fundus.

The impossibility of rehabilitation of visual acuity, but the possibility of surgically resolving the exotropia from an aesthetic aspect were explained to the patient. After completing the additional preoperative examinations (determination of the angle of deviation (50Δ), anesthesiological and laboratory tests), surgical treatment was initiated. On the left eye, a recession of the lateral rectus muscle of 7.1 mm and a resection of the medial rectus muscle of 6.1 mm were performed. The patient was brought into orthophoria, an aesthetically satisfactory effect, of course without improvement in visual function and without the appearance of double images. By the time this paper was published, the aesthetic effect of the surgery was satisfactory.

Discussion

Myelinated retinal nerve fibers (MRNF) fundoscopically appear as striatal opacities along the course of retinal nerve fibers. They are most often asymptomatic and their detection is incidental during fundoscopic examination. However, in some situations, they are associated with certain systemic conditions such as neurofibromatosis, vitreoretinopathy with skeletal malformations, and Gorlin syndrome^[2,6]. In Straatsma syndrome, MRNF are accompanied by axial myopia and amblyopia, contributing to visual impairment. The presence of myelinated nerve fibers is a rare condition, estimated to be present in less than 1% of patients during routine ophthalmological examinations^[1]. It is most often a benign condition, however, it can affect visual function according to the localization and extension of the myelination plaques as well as macula involvement. The formation of myelination plaques in the retina is not fully understood. Myelination as a process begins in the fifth month of pregnancy and ends shortly before birth. The lamina cribrosa is thought to act as a barrier to the myelination process, and disruption of this structure is likely to play a role in myelination continuing to involve retinal nerve fibers. The barrier role of the lamina cribrosa is

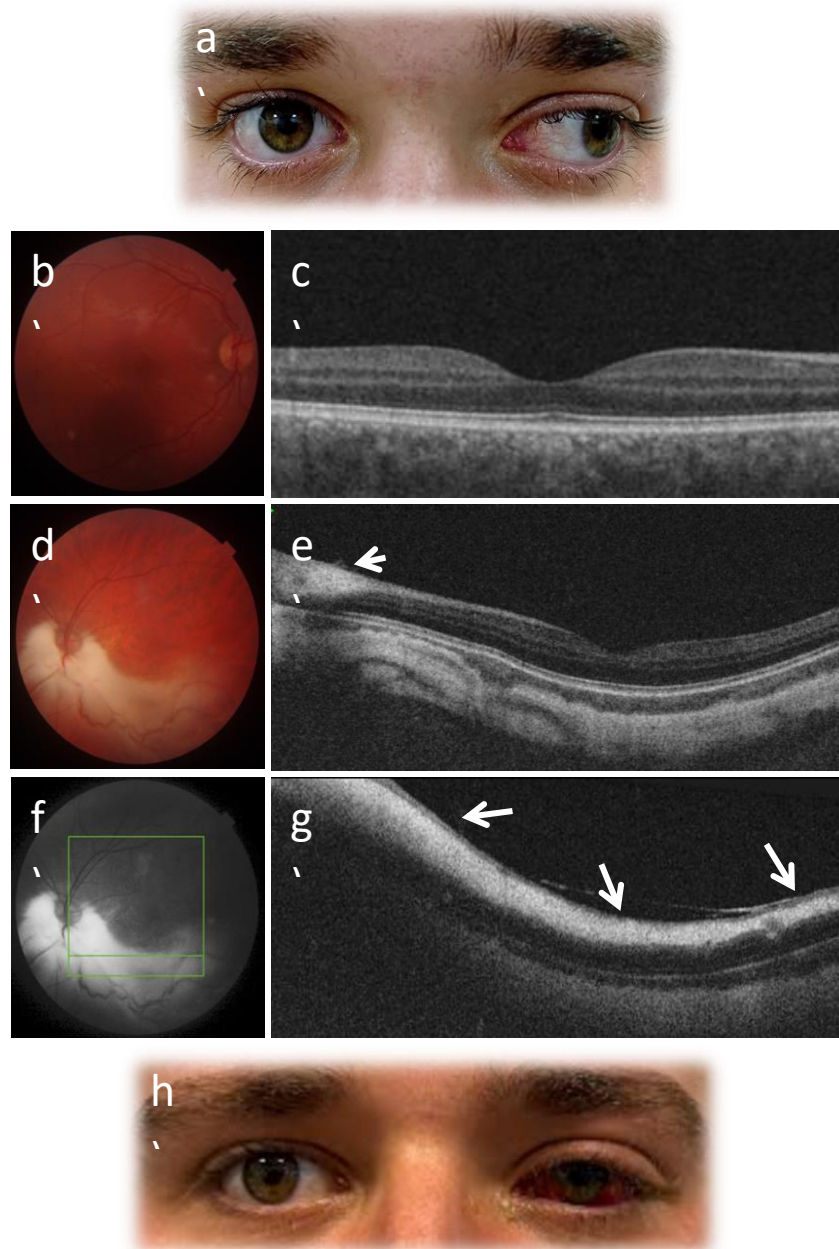


Fig. 1. a) Exotropia of the left eye in the patient's primary position; b) Fundus photograph; c) Optical coherence tomography of the macular region of the right eye - normal morphological features; d) Fundus photograph of the left eye - hypoplastic and tilted disc, myelinated nerve fibers extending from the papilla to the inferior temporal arcade, tortuosity of the surrounding blood vessels; e) Optical coherence tomography of the macular region of the left eye, aspect of myopic-staphylomatous tomogram, myelinated nerve fibers (white arrow), foveolar umbo present; f) Red-free fundus photograph, showing myelinated nerve fibers; g) OCT cross-section, hyperreflective-myelinated nerve fibers (white arrows), myopic-staphylomatous configuration of the tomogram; h) Two days postoperatively, subconjunctival blood in the nasal and lower sectors of the left eye, aesthetically satisfactory orthophoria achieved.

likely due to the dense aggregation of astrocytes in this region, which may act as a barrier to prevent oligodendrocyte migration to the retina^[7,8]. MRNFs are most commonly continuous with the optic nerve head. They are fern-shaped and extend along the blood arcades, and it is important that they respect the horizontal raphe. Although less frequently, they can also occur separately from the optic disc and on the periphery of the retina^[9].

Patients with MRNFs more often have axial than refractive myopia. Thus, some theories suggest that axial myopia of the eye causes late closure of the lamina cribrosa, which leads to myelination of the retinal nerve fibers with subsequent amblyopia^[1,2,10]. However, the existence of reverse Straatsma syndrome, in which hyperopia occurs instead of myopia, indicates that other factors are likely involved in this myelination process.

According to localization, three types of MRNF have been described: type 1 (most common)-myelination extends along the superior temporal arcade, type 2 (rare)-myelination extends along both temporal arcades, has the worst prognosis for vision, and type 3-myelination that is not continuous with the optic disc^[8,11]. Our patient has myelination that extends along the inferior temporal arcade, in contrast to the classic type 1 MRNF that extends along the superior temporal arcade. In rare cases, myelination can also involve the macular region, which is accompanied by severe photophobia and severe visual impairment. Several studies have shown that the larger the MRNF area, the greater the myopia and the worse the visual function. Patients with less than 5 hours of MRNF on the hour scale have better visual function^[12]. Our patient had about 6 hours of MRNF involvement.

The main problem in patients with Straatsma syndrome is the associated amblyopia and its treatment. The degree of anisometropia is one of the main risk factors for the outcome of amblyopia treatment in these patients^[13]. According to Hittner and Antoszyk, patients with a high degree of anisometropia (average -13.00 D) have lower visual acuity after amblyopia treatment^[14]. The case described above belongs to patients with a high degree of anisometropia and axial myopia of -16.00 D.

Occlusion treatment in patients with Straatsma is associated with a poorer outcome than in patients with isolated anisometropic amblyopia^[9]. This data suggests that MRNF probably plays a role in the amblyopia itself in patients with Straatsma, i.e. amblyopia in these patients is a combination of organic etiology supplemented by functional amblyopia^[1,2]. The presence of a hypoplastic optic disc in some patients with Straatsma, as in our case, is further evidence of a possible organic background for significant vision loss and poor outcome despite aggressive treatment of amblyopia. Cases of patients with Straatsma syndrome have been described, where poor visual function is also associated with disruption of the ellipsoidal zone of the retina, as further evidence of an organic background to the problem^[15]. In the case described above, the ellipsoidal zone was intact. Another risk factor associated with poor visual outcome in patients with Straatsma is concomitant strabismus^[16]. It was also present in our case, in the form of exotropia with a large angle of deviation of 25°. Although this syndrome is associated with a poor visual prognosis, intensive occlusion treatment should be initiated as early as possible, as well as prescription of cycloplegic refraction, due to the unexpected and variable response to therapy^[17]. Cases have been described in which, despite poor prognostic characteristics of the patient, the application of appropriate and timely therapy (early aggressive amblyopia treatment, contact lens-based aniseikonia control, and timely alignment surgery), has resulted in good long-term outcomes^[13].

Conclusion

Our patient had several risk factors for poor outcome in terms of visual function: high axial myopia and anisometropia (-16.00D), MRNF greater than 5 o'clock in circumference and strabismus-exotropia with a large angle deviation (25°) as well as optic nerve head hypoplasia. However, the main unfavorable factor is that the patient presented for ophthalmological evaluation at the age of 22 years, long-term amblyopia that makes it impossible to functionally improve visual function.

Therefore, timely detection of this syndrome, even in early childhood, and initiation of aggressive treatment of amblyopia and appropriate refractive correction should be implemented in order to obtain the most optimal results for the rehabilitation of visual function in these patients.

Conflict of interest statement. None declared.

Written informed consent for publication was obtained from the patient.

References

1. Straatsma BR, Heckenlively JR, Foos RY, Shahinian JK. Myelinated retinal nerve fibers associated with ipsilateral myopia, amblyopia, and strabismus. *Am J Ophthalmol* 1979; 88(3 Pt 1): 506-510. doi: 10.1016/0002-9394(79)90655-x.
2. Tarabishy AB, Alexandrou TJ, Traboulsi EI. Syndrome of myelinated retinal nerve fibers, myopia, and amblyopia: a review. *Surv Ophthalmol* 2007; 52(6): 588-596. doi: 10.1016/j.survophthal.2007.08.016.
3. Juhn AT, Houston SK 3rd, Mehta S. Bilateral Straatsma syndrome with nystagmus. *Retin Cases Brief Rep* 2015; 9(3): 198-200. doi: 10.1097/ICB.000000000000137.
4. Wang Y, Gonzalez C. Unilateral myelinated nerve fibers associated with hypertropia, strabismus and amblyopia? Reverse straatsma syndrome? *Binocul Vis Strabismus Q* 2008; 23(4): 235-237. PMID: 19132949.
5. Sevik MO, Aykut A, Karaman NF, Şahin Ö. Straatsma Syndrome: Should Visual Prognostic Factors Be Taken into Account? A Case Report. *Turk J Ophthalmol* 2021; 51(6): 398-402. doi: 10.4274/tjo.galenos.2021.32470.
6. Parulekar MV, Elston JS. Acquired retinal myelination in neurofibromatosis 1. *Arch Ophthalmol* 2002; 120(5): 659-655. PMID: 12003622.
7. Ramkumar HL, Verma R, Ferreyra HA, Robbins SL. Myelinated Retinal Nerve Fiber Layer (RNFL): A Comprehensive Review. *Int Ophthalmol Clin* 2018; 58(4): 147-156. doi: 10.1097/IIO.0000000000000239.
8. Hunter SF, Leavitt JA, Rodriguez M. Direct observation of myelination in vivo in the mature human central nervous system. A model for the behaviour of oligodendrocyte progenitors and their progeny. *Brain* 1997; 120 (Pt 11): 2071-2082. doi: 10.1093/brain/120.11.2071.
9. Ellis GS Jr, Frey T, Gouterman RZ. Myelinated nerve fibers, axial myopia, and refractory amblyopia: an organic disease. *J Pediatr Ophthalmol Strabismus* 1987; 24(3): 111-119. doi: 10.3928/0191-3913-19870501-04.
10. Schmidt D, Meyer JH, Brandt-Dohrn J. Wide-spread myelinated nerve fibers of the optic disc: do they influence the development of myopia? *Int Ophthalmol* 1996-1997; 20(5): 263-268. doi: 10.1007/BF00131921.

11. Choudhary A, Kathare R, Gandhi P, Yadav NK, Prabhu V, Bavaskar S *et al.* Characteristics of myelinated retinal nerve fibres in associated straatsma syndrome. *Eur J Ophthalmol* 2025; 35(2): 689-694. doi: 10.1177/11206721241272182.
12. Kee C, Hwang JM. Visual prognosis of amblyopia associated with myelinated retinal nerve fibers. *Am J Ophthalmol* 2005; 139(2): 259-265. doi: 10.1016/j.ajo.2004.09.018.
13. Ben Addou Idrissi S, Moutei H, Bennis A, Chraibi F, Abdellaoui M, Benatiya Andaloussi I. Insights into Straatsma syndrome: a pediatric case report. *Strabismus*. 2025; 1-7. doi: 10.1080/09273972.2025.2564760.
14. Hittner HM, Antoszyk JH. Unilateral peripapillary myelinated nerve fibers with myopia and/or amblyopia. *Arch Ophthalmol* 1987; 105(7): 943-948. doi: 10.1001/archopht.1987.01060070079033.
15. Bass SJ, Westcott J, Sherman J. OCT in a Myelinated Retinal Nerve Fiber Syndrome with Reduced Vision. *Optom Vis Sci* 2016; 93(10): 1285-1291. doi: 10.1097/OPX.0000000000000951.
16. Yalcin E, Balci O, Akingol Z. Association of extensive myelinated nerve fibers and high degree myopia: case report. *Indian J Ophthalmol* 2013; 61(10): 606-607. doi: 10.4103/0301-4738.118455.
17. Karakosta C, Paraskevopoulos K, Bisoukis A, Bougioukas K, Kokolaki A. Straatsma Syndrome: A Case Series. *Cureus* 2022; 14(9): e29779. doi: 10.7759/cureus.29779.