Received: October 5, 2026
Accepted: October 19, 2026
Published: November 27, 2026

Acad Med J 2026;6(3):203-207
UDC:616.342.2-002-073.756.8:004
Case report

STUMP APPENDICITIS 11 YEARS AFTER OPEN APPENDECTOMY: A CASE REPORT

Makashchieva Maja[1], Lazarova Ana[2], Endzekceva Aleksandra[1], Radeva Katerina[1], Petrovska Tanja[1,2]

[1]Faculty of Medical Sciences, Goce Delcev University, Stip, Republic of North Macedonia
[2]University Clinic for Surgical Disease "St. Naum Ohridski", Skopje, Republic of North Macedonia
e-mail: makascievamaja@gmail.com

Abstract

Introduction: Stump appendicitis is a rare complication of appendectomy resulting from inflammation of residual appendiceal tissue.

Case report: We present the case of a 27-year-old woman who developed acute right lower quadrant abdominal pain, nausea, vomiting, and low-grade fever 11 years after an open appendectomy. Laboratory investigations showed elevated C-reactive protein (95 mg/L), mild leukocytosis (11.4×10⁹/L), mild neutrophilia (71%), and thrombocytopenia (118×10⁹/L). Abdominal ultrasound was non-diagnostic. Contrast-enhanced computed tomography (CT) demonstrated an inflamed appendiceal stump measuring 17 mm in diameter and 26 mm in length with surrounding inflammatory fat stranding, small reactive lymph nodes, and a localized fluid collection. No appendicolith, extraluminal gas, focal wall defect, or other CT signs of perforation were identified. The patient underwent emergency diagnostic laparoscopy, followed by conversion to midline laparotomy, completion appendectomy, cecal suture, abdominal lavage, and drainage. Histopathological examination confirmed acute phlegmonous inflammation of the appendiceal stump with acute fibrinopurulent peritonitis, without atypia or malignant changes. The postoperative course was uneventful, and the patient was discharged on the first postoperative day.

Conclusion: This case emphasizes that stump appendicitis should remain in the differential diagnosis of right lower quadrant pain even years after appendectomy and highlights the important role of CT in establishing the diagnosis.

Keywords: stump appendicitis; computed tomography; appendiceal remnant; appendectomy; case report

Introduction

Stump appendicitis refers to acute inflammation of the remaining appendiceal tissue and represents a rare complication following appendectomy. Maintaining clinical suspicion of this condition in patients with right lower quadrant abdominal pain and a history of appendectomy is essential to avoid delays in diagnosis and treatment. Computed tomography is particularly valuable for establishing the preoperative diagnosis and differentiating stump appendicitis from other potential causes of the patient's symptoms[1]. The exact incidence and prevalence of stump appendicitis remain uncertain, and the condition may be underrecognized and underreported in the medical literature[2]. Reported cases have involved patients between 11 and 72 years of age, with stump appendicitis occurring anywhere from 2 months to 51 years

after the initial appendectomy. A longer residual appendiceal stump has been identified as a potential risk factor, with reported stump lengths ranging from 0.5 to 6.5 cm[3-6].
Because stump appendicitis is often diagnosed late, patients are at greater risk of developing perforation and subsequent complications[10,11]. The clinical presentation of stump appendicitis closely resembles that of acute primary appendicitis. Patients typically experience abdominal pain that initially develops around the umbilicus and subsequently localizes to the right lower quadrant, often accompanied by anorexia, nausea, and vomiting[12].

Case report

A 27-year-old woman presented to the emergency department with a 24-hour history of right lower quadrant abdominal pain, nausea, vomiting, and low-grade fever. Physical examination revealed well-healed surgical scar in the right lower quadrant from the previous open appendectomy, with tenderness, muscular guarding, and rebound tenderness in the same region. Her medical history was significant for open appendectomy performed 11 years earlier. Laboratory evaluation revealed an elevated C-reactive protein level of 95 mg/L, while the leukocyte count was only mildly elevated (11×10^9/L). Other available laboratory parameters were within normal limits. Given the patient's age and clinical presentation, gynecological, urinary, and gastrointestinal/ileocecal causes of right lower quadrant pain were also considered. Ultrasound was initially performed as the first-line imaging modality; however, the examination was non-diagnostic, with no significant abnormalities identified. Contrast-enhanced abdominal computed tomography demonstrated an inflamed residual appendiceal stump measuring 17 mm in diameter and 26 mm in length, with surrounding fat stranding, small reactive lymph nodes, localized fluid collection, and minimal free pelvic fluid, consistent with stump appendicitis.

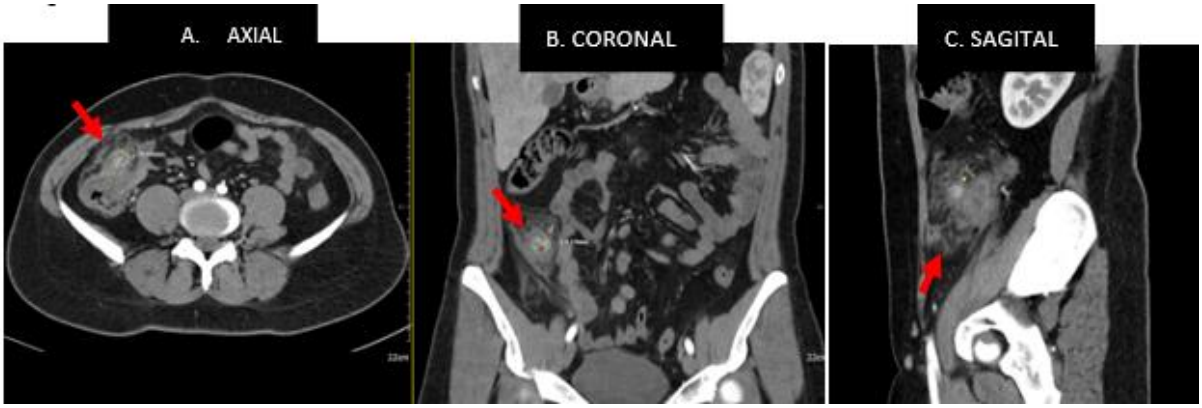

Fig. 1. Contrast-enhanced CT demonstrating an inflammatory process in the ileocecal region arising from an inflamed appendiceal stump. The stump is 26 mm long (Figure A), thickened and stratified and measuring 17 mm in diameter (Figure B), with surrounding inflammatory fat stranding, small reactive lymph nodes, and a localized adjacent fluid collection (red arrow). A small hyperdense focus was visualized, suspicious for an area of hemorrhage best seen on Figure C (yellow arrow).

Additionally, a small hyperdense area was identified within the appendiceal stump, with hemorrhagic content considered in the differential diagnosis. The remaining abdominal structures were without significant pathological findings. Emergency diagnostic laparoscopy was initiated but converted to a midline laparotomy due to the presence of peritonitis and the local inflammatory changes. Completion appendectomy, cecal suture repair, abdominal lavage,

and drainage were performed. Gross and microscopic examination of the resected specimen demonstrated a segment of vermiform appendix measuring 3 mm in length, with a circumference of 1 cm and attached adipose tissue measuring 2.5 cm in thickness. Microscopically, the specimen showed preserved mucosal folds with moderate to marked predominantly polymorphonuclear inflammatory infiltration involving the appendiceal wall, with phlegmonous propagation and multifocal fresh hemorrhage. Foci of suppuration and fibrinopurulent serosal exudation were identified. One specimen also contained a reactive enlarged lymph node. No atypia or malignant changes were identified. The final histopathological diagnosis was acute phlegmonous inflammation of a segment of the vermiform appendix with acute fibrinopurulent peritonitis. The postoperative course was uneventful, and the patient was discharged on postoperative day two in good general condition. No postoperative complication was documented.

Discussion

Acute appendicitis is one of the most common conditions requiring emergency surgical intervention, with appendectomy accounting for a substantial proportion of emergency surgical procedures. Although stump appendicitis is a recognized complication following appendectomy, it occurs infrequently compared with other postoperative complications, such as surgical site infection, pelvic abscess, and adhesive intestinal obstruction[10]. In our patient, stump appendicitis occurred 11 years after the initial open appendectomy, highlighting that this complication may present even many years after the original surgery.

Laparoscopic appendectomy has become an established and widely used approach for the surgical management of acute appendicitis. The increasing adoption of this technique has raised the possibility of a higher incidence of stump appendicitis[4,7,5,8]. This has been attributed to technical limitations, including a restricted operative field, lack of three-dimensional visualization, and absence of tactile feedback, which may contribute to leaving a longer appendiceal remnant[8]. However, among 36 reported cases of stump appendicitis, only 10 occurred following laparoscopic appendectomy[9]. In contrast to the cases associated with laparoscopic appendectomy, our patient developed stump appendicitis following an open appendectomy, demonstrating that this complication is not limited to the laparoscopic approach. To date, available evidence has not established a definitive association between the laparoscopic approach and the development of stump appendicitis. Stump appendicitis may occur following either open or laparoscopic appendectomy, although a definitive increase in its incidence associated with the laparoscopic approach is yet be established[6,17]. The size of the residual appendiceal stump has been discussed as a potential risk factor. A systematic review suggested that stump appendicitis can occur with residual appendiceal tissue exceeding 0.5 cm [3], while other reports have emphasized the importance of leaving a short appendiceal stump during the initial operation [6,12]. In the present case, the reported 17 mm measurement refers to the stump diameter on CT and should not be interpreted as its longitudinal stump length.

In a previous study, abdominal pain was reported in 93% of patients, with 77% experiencing pain localized to the right lower quadrant. Gastrointestinal symptoms, including nausea and vomiting, were present in 57% of cases[15,16]. Imaging plays an important role in establishing the diagnosis. Ultrasound may demonstrate an inflamed appendiceal remnant, but CT is particularly useful for identifying the residual stump and assessing its surrounding inflammatory changes and possible complications[4,5,15]. In the CT series by Enzerra *et al*., inflammatory changes surrounding the appendiceal stump were consistently demonstrated, with appendicolith and peristump abscess reported in a proportion of patients[5]. In contrast, no appendicolith or CT evidence of perforation was identified in our patient, and the inflammatory process was associated with a localized fluid collection without extraluminal gas or a focal wall

defect. Recognition of a residual appendiceal stump and its associated inflammatory changes on CT can establish the diagnosis and facilitate appropriate surgical management. The total number of reported cases remains limited, and further multicenter studies would be useful to better characterize risk factors, imaging findings, and optimal management.

Conclusion

In conclusion, stump appendicitis is a rare but potentially serious complication of appendectomy that may be overlooked or mistaken for other causes of right lower quadrant pain. This case highlights an important imaging consideration: a history of previous appendectomy should not lead to exclusion of appendicitis when a patient presents with compatible right lower quadrant symptoms. Maintaining a high index of suspicion, particularly in patients presenting with compatible clinical symptoms, is essential for timely diagnosis and appropriate management. Computed tomography plays a crucial role in confirming the diagnosis and identifying associated complications, allowing prompt surgical treatment when indicated. Therefore, radiologists and clinicians should be aware of this uncommon condition and consider it in patients presenting with right lower quadrant pain, even years after appendectomy. Although recent systematic reviews and CT series have improved understanding of this condition, the evidence base remains limited by its rarity, and further multicenter research is warranted.

Conflict of interest statement. None declared.
Written consent of the patients was obtained.

References

1. Uludag M, Isgor A, Basak M. Stump appendicitis is a rare delayed complication of appendectomy: A case report. *World J Gastroenterol* 2006; 12(33): 5401-5403. doi: 10.3748/wjg.v12.i33.5401.
2. Watkins BP, Kothari SN, Landercasper J. Stump appendicitis: case report and review. *Surg Laparosc Endosc Percutan Tech* 2004; 14(3): 167-171. doi: 10.1097/01.sle.0000129392.75673.97.
3. Manatakis DK, Aheimastos V, Antonopoulou MI, Agalianos C, Tsiaoussis J, Xynos E. Unfinished business: a systematic review of stump appendicitis. *World J Surg* 2019; 43(11): 2756-2761. doi: 10.1007/s00268-019-05101-z.
4. Shin LK, Halpern D, Weston SR, Meiner EM, Katz DS. Prospective CT diagnosis of stump appendicitis. *AJR Am J Roentgenol* 2005; 184(3 Suppl): S62-S64. doi: 10.2214/ajr.184.3_supplement.01840s62.
5. Enzerra MD, Ranieri DM, Pickhardt PJ. Stump appendicitis: clinical and CT findings. *AJR Am J Roentgenol* 2020; 215(6): 1363-1369. doi: 10.2214/AJR.20.22911.
6. Erzurum VZ, Kasirajan K, Hashmi M. Stump appendicitis: a case report. *J Laparoendosc Adv Surg Tech A* 1997; 7(6): 389-391. doi: 10.1089/lap.1997.7.389.
7. Mangi AA, Berger DL. Stump appendicitis. *Am Surg* 2000; 66(8): 739-741. PMID: 10966030.
8. Durgun AV, Baca B, Ersoy Y, Kapan M. Stump appendicitis and generalized peritonitis due to incomplete appendectomy. *Tech Coloproctol* 2003; 7(2): 102-104. doi: 10.1007/s10151-003-0018-4.
9. Nielsen-Breining M, Nordentoft T. Stump appendicitis after laparoscopic appendectomy. *Ugeskr Laeger* 2005; 167: 2067-2068.
10. Walsh DC, Roediger WE. Stump appendicitis--a potential problem after laparoscopic appendicectomy. *Surg Laparosc Endosc* 1997; 7(4): 357-358. PMID: 9282774.

11. Roche-Nagle G, Gallagher C, Kilgallen C, Caldwell M. Stump appendicitis: a rare but important entity. *Surgeon* 2005; 3(1): 53-54. doi: 10.1016/s1479-666x(05)80015-0.
12. Roberts KE, Starker LF, Duffy AJ, Bell RL, Bokhari J. Stump appendicitis: a surgeon's dilemma. *JSLS* 2011; 15(3): 373-378. doi: 10.4293/108680811X13125733356954.
13. Liang MK, Lo HG, Marks JL. Stump appendicitis: a comprehensive review of literature. *Am Surg* 2006; 72(2): 162-166. PMID: 16536249.
14. Greenberg JJ, Esposito TJ. Appendicitis after laparoscopic appendectomy: a warning. *J Laparoendosc Surg* 1996; 6(3): 185-187. doi: 10.1089/lps.1996.6.185.
15. Monsomboon A, Nelson BP, Andrus P, Tsung JW. Point-of-care ultrasound diagnosis of stump appendicitis in the emergency department. *Ultrasound J* 2019; 11(1): 12. doi: 10.1186/s13089-019-0128-5.
16. Subramanian A, Liang MK. A 60-year literature review of stump appendicitis: the need for a critical view. *Am J Surg* 2012; 203(4): 503-507. doi: 10.1016/j. amjsurg.2011.04.009.
17. Shah T, Gupta RK, Karkee RJ, Agarwal CS. Recurrent pain abdomen following appendectomy: stump appendicitis, a surgeon's dilemma. *Clin Case Rep* 2017; 5(3): 215-217. doi: 10.1002/ccr3.781.