Received: October 7, 2026
Accepted: October 28, 2026
Published:November 27, 2026

Acad Med J 2026;6(3):242-251
UDC: 616.314.16-089.87-073.75
Case report

RADIOGRAPHIC EVALUATION OF PERIAPICAL HEALING FOLLOWING APICOECTOMY

Jakimovski Rade[1], Gjorovska Maja[2], Kacarska Marina[1,2]

[1]Department of Oral Surgery Faculty of Dentistry, Ss. Cyril and Methodius University in Skopje, Republic of North Macedonia
[2]PHO University Clinical Center St. Panteleimon, Oral Surgery Clinic, Skopje, Republic of North Macedonia
e-mail: jakimovskirade@gmail.com

Abstract

Introduction: Healing of the periapical wound following apicoectomy may be influenced by multiple biological and clinical factors. The extent of the intraoperative osseous defect and its configuration may affect the process of bone regeneration and the radiographic appearance of the healing.

Case report: This case series describes the relationship between the configuration of the intraoperative osseous defect and the pattern of periapical healing following apicoectomy through radiographic evaluation of the healing process at different time points: preoperatively, immediately postoperatively and 3-6 months after surgery. The results showed that periapical healing following apicoectomy was influenced by the intraoperative osseous defect configuration. Complete healing was observed in cases with five osseous walls, while the case with through-and-through defect demonstrated healing by scar tissue formation.

Keywords: apicoectomy, periapical healing, radiographic evaluation, intraoperative osseous defect

Introduction

The primary goal of endodontic therapy is to preserve teeth with irreversibly compromised pulp, prevent or treat apical periodontitis[1], and restore teeth function. This goal can be accomplished by eliminating the necrotic pulp, infected dentin and completely eradicating the pathologic microorganisms through mechanical and chemical debridement of the root canals followed by hermetic obturation[1,2]. Although conventional endodontic treatment has a high success rate[3], apical periodontitis can still occur as a result of factors such as persistent intraradicular or extraradicular infection, root fractures, foreign body reaction or a true cyst formation. In general, the causes for conventional endodontic treatment failure are bacteriological in origin[4-7].

Apicoectomy is a surgical procedure which involves creating an osseous window to reach the infected periapical tissues, its complete removal and resection of the apical proportion of the affected root[1]. This procedure aims to eliminate the persistent source of inflammation and to establish conditions favorable for healing of the periapical tissues. Studies show that resecting the apical 3 mm of the affected root reduces 98% of the apical ramifications and 93% of the lateral canals[8,9].

Healing involves a complex sequence of inflammatory, proliferative and remodeling processes, although not mutually exclusive[8]. No wound in the human body heals without scar

formation[8]. Several factors can influence the outcome of the elective apicoectomy and impede or promote postoperative healing, such as the quality of root canal treatment, root end seal, surgical technique and the size and anatomical characteristics of the osseous defect[11-14].

Periapical osseous defects may present with different configurations depending on the extent of the underlying inflammatory lesion. Defects with a greater number of osseous walls provide better environment for healing, whereas extensive defects involving the loss of one or more cortical plates are associated with decreased blood supply to the wound, increased internal pressure and greater tension[8]. The relationship between the configuration of the periapical bone defect and the pattern of periapical healing remains clinically relevant when evaluating the outcomes of apicoectomy[11].

Radiographic examination is routinely used for assessing the healing of the periapical tissues following root canal treatment either conventionally or surgically[1]. Sequential retroalveolar or panoramic radiographs allow changes in the quantitative and qualitative characteristics to be documented over time. Comparison of preoperative, immediate postoperative and delayed follow-up radiographs provides information regarding the progression of osseous healing and eventual resolution or persistence of periapical radiolucency[15].

The aim of this paper was to radiologically evaluate the periapical healing after apicectomy and its relation to the osseous configuration.

Case reports

Case No. 1.

A 24-year-old healthy female was referred to the PHO University Dental Clinical Centre St. Panteleimon, Oral Surgery Clinic due to reemerging pain caused by temporary obturation of tooth 45 after endodontic treatment. Intraorally, slight erythema and tenderness on palpation in the apical area of tooth 45 was present, as well as sensitivity on vertical percussion. Panoramic radiograph depicted a small apical irregular radiolucency, enlarged *spatium periodontale* and loss of *lamina dura* (Figure 1). Based on the clinical and paraclinical findings, a diagnosis of *abscessus dentoalveolaris chronica* was established and the patient was prescribed antibiotic therapy (amoxicillin 875 mg + clavulanic acid 125 mg 1 x 12h for 7 days).



Fig. 1. Preoperative, small irregular refication, enlargement of paradontal space and loss of the continuity of lamina dura on tooth 45

After the acute symptoms had subsided, the patient was scheduled for apicoectomy. Informed consent was signed. After application of inferior alveolar nerve block and buccal nerve terminal anesthesia (two carpules of 4% articaine with 1:100000 epinephrine Artinibsa®-Turkey), a triangular mucoperiosteal flap was made (blade No. 15), starting with medially positioned

vertical incision, followed by a sulcular incision. After flap elevation, periapical osteotomy was made using a high-speed carbide round bur and copious irrigation. The apical granulation tissue was completely removed until healthy bone margins were obtained. Approximately 3 mm of apical root portion was resected under zero-degree bevel. The root canal was cleaned and shaped using hand files, and then rinsed with 1% iodine solution and 3% H_2O_2. Prior to canal obturation, hemostasis was achieved and the root canal was dried. Intraoperative orthograde canal obturation with iodoform phosphate cement and gutta-percha was made. After debris removal, the osseous configuration was assessed and mucoperiosteal flap sutured (3-0 silk sutures). At the first postoperative follow-up, the patient complained of ipsilateral chin and lower lip numbness due to the proximity of the surgical area to the mental nerve. Chymoral S® (tripsin, hemotripsin, serropeptase, 1x24h) was prescribed to accelerate healing, reduce swelling and inflammation[16]. Sutures were removed seven days postoperatively.

The immediate postoperative radiograph demonstrated enlarged radiolucency due to periapical surgery (Figure 2). After 6 months, retroalveolar radiograph showed peripheral new bone formation and fine bone mesh in the lesion center (Figure 3). There was no increase in lamina dura width and *spatium periodontale*, which indicated favorable healing according to Andreasen and Rud findings on correlation between histology and radiography[15].

After 12 months, a normal bone structure resembling the neighboring healthy bone, normal *spatium periodontale* and *lamina dura* were observed (Figure 4), indicating complete healing according to the radiographic criteria for healing assessment by Andreasen and Rud[17].



Fig. 2. Immediate postoperative, operative defect and root canal obturation



Fig. 3. 6 months postoperatively, new bone formation
on the periphery and fine bone mesh in the center of the lesion

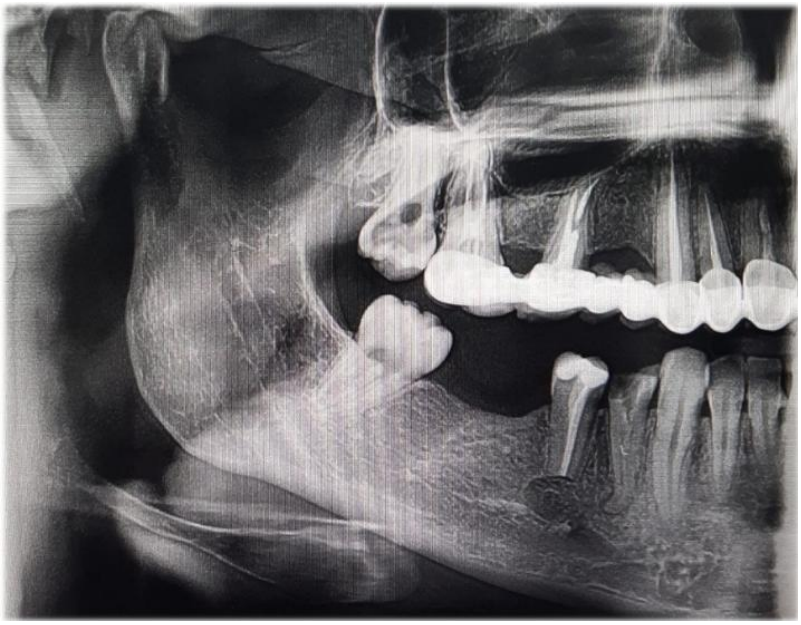

Fig. 4. 12 months postoperatvelu, normal bone structure resembling neigboring bone, normal width of the periodontal space and lamina dura

Case No. 2.

A 46-year-old healthy female presented to the PHO University Dental Clinical Centre St. Panteleimon, Oral Surgery Clinic, due to upper jaw pain lasting for several months. Intraoral examination showed slight erythema and tenderness on palpation in the apical region of tooth 14. Vertical percussion test was positive. Panoramic and retroalveolar radiographs depicted small, round well-defined periapical radiolucency, enlarged *spatium periodontale* and loss of *lamina dura* (Figure 5 and Figure 6). Based on clinical and paraclinical findings, a diagnosis of *abscessus dentoalveolaris chronica* was made and the patient was scheduled for surgery. The patient signed an informed consent for surgery and use of data for scientific purposes.



Fig. 5. Preoperative, small round well-difined pariapical rarefication, elarged parodontal space and loss of the continuity of lamina dura on tooth 14

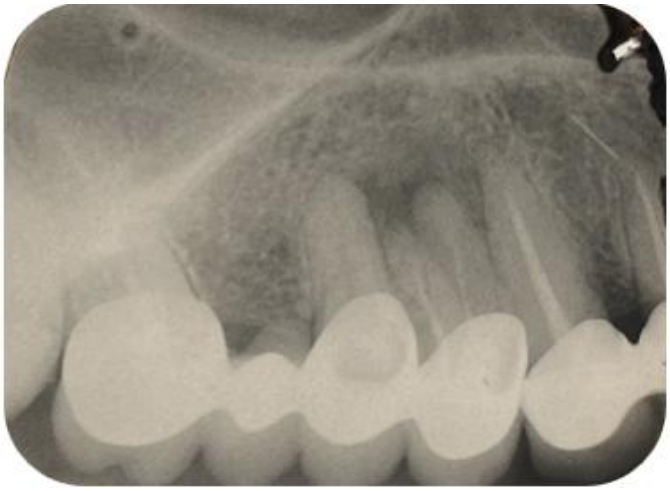

Fig. 6. Preoperative, small round well-defined pariapical rarefication, elarged parodontal space and loss of the continuity of lamina dura

Terminal plexus anesthesia for the medial superior alveolar branches and terminal anesthesia for the greater palatine nerve was applied (two carpules of 4% articaine with 1:100000 epinephrine). After elevation of a full-thickness trapezoidal flap, osteotomy, curettage and root resection of buccal and palatal roots were performed. Root-end preparations were made, then filled with iodoform phosphate cement. Before suturing, the osseous configuration was assessed. The immediate postoperative radiograph showed enlarged periapical radiolucency due to apicoectomy (Figure 7). Radiographic evaluation after 6 months clearly depicted periapical radiolucency reduction and new bone formation along lesion periphery (Figure 8, Figure 9). The rarefaction outline was irregular, extension of the periodontal space into the rarefaction was angular, without widening of *lamina dura* which indicated favorable healing without or with mild inflammation according to the criteria by Andreasen and Rud [15].



Fig. 7. Immediate postoperative, operative defect and root-end obturation



Fig. 8. Six months postoperatively, reduction of the periapical rarefication, new coarse and fine bone formation on the periphery of the lesion



Fig. 9. SIx months postoperatively, reduction of the periapical rarefication, new bone formation on the periphery of the lesion on tooth 14

Case No. 3.

A 23-year-old healthy male was referred to the PHO University Dental Clinic Centre St. Panteleimon, Oral Surgery Clinic, for apical surgery. Preoperative panoramic radiograph showed large ovoid unilocular radiolucency with well-defined osteosclerotic margins associated with apical aspect of avital tooth 11 (Figure 10), characteristic features for radicular cyst. Positive history of trauma to tooth 11 explained the large pulpal cavum and pulpal foramen, which indicated that the trauma had occurred in the early years of tooth maturating stage, relatively soon after its eruption. Infraorbital nerve block and nasopalatine nerve block were administered (4% articaine with 1:100000 epinephrine Artinibsa®). Then. a sulcular trapezoidal flap was elevated exposing buccal lamina defect. The cystic lesion was enucleated *in toto*, exposing a palatal cortical defect. The rest of the surgery was performed as described in case no.1. Post-surgery the patient was prescribed an antibiotic (amoxicillin 875 mg + clavulanic acid 125 mg, 1x12h for 5 days) and Chymoral S® (trypsin, hemotrypsin, serrapeptase) 1x24h. At the first postoperative follow-up, the patient complained of mild pain, which was to be expected. At the second follow-up, the sutures were removed. The patient was feeling well.

The immediate postoperative radiograph demonstrated the extent of periapical surgical defect following apicoectomy (Figure 11). After 3 months, control panoramic and retroalveolar radiographs showed reduction of the periapical radiolucency due to new bone formation, which was more radiolucent than the neighboring healthy bone (Figure 12, Figure 13). The outline of the rarefaction was irregular, extension of the periodontal space into the rarefaction was angular,



Fig. 10. Preoperative, large ovoid unilocular rarefication with well-defined osteosclerotic boarders associated with apical aspect of tooth 11



Fig. 11. Immediate postoperatively, periapical operative defect and root canal obturation on tooth 11



Fig. 12. Three months postoperatively, reduction of the periapical rarefication, new bone formation on the periphery which is more radiolucent than the neighboring healthy bone

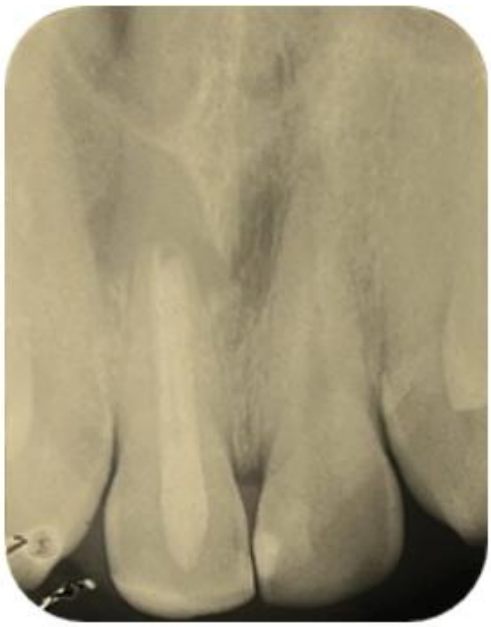

Fig. 13. Three months postoperatively, rarefication in the center persists, outline of the rarefaction is irregular, angular extension of the periodontal space into the rarefaction, normal width of lamina dura

with no increase in width of *lamina dura*. This indicated favorable but incomplete healing, with scar tissue formation, with no or mild inflammation according to the findings of Andreasen and Rud on the correlation between histology and radiography[15].

Discussion

Periapical surgery aims to remove the apical pathology, obtain tight canal obturation thus creating optimal circumstances for favorable outcome: complete periapical healing and regeneration of the periodontal tissues. Many factors may influence the outcome. Among the determining one is the number and condition of the bony walls encircling the periapical lesion, with emphasis on the cortical plates. Their integrity is mainly jeopardized by periapical inflammation. After removal of periapical lesions in case no.1 and no.2, the bony crypts maintained healthy five bony walls. The 6th wall, the buccal cortical plate, although present, was removed for optimal visual and instrumental surgical access to the periapical area. Such intraoperative findings sustained favorable postoperative outcome.

Case No. 3 differed from the previously described cases because of the extension of the large radicular cyst that had caused loss of both cortical plates, resulting in through-and-through (tunnel) osseous defect. After enucleation of the lesion, the bony crypt presented with four bony walls. Such operative findings were in favor of incomplete scar healing.

The postoperative healing was evaluated on extraoral and intraoral radiographs at different time intervals, preoperatively, immediately postoperatively and 3-6 months after the surgical procedure as suggested by Andreasen and Rud [15,17].

The Andreasen and Rud classification provides a practical method for evaluating the healing after apicoectomy and distinguishing complete healing from incomplete healing associated with scar tissue formation, uncertain healing and unsatisfactory healing, thereby facilitating the clinical decision-making regarding the need for retreatment [17]. Immediately after apicoectomy, the radiographic findings of the periapical area resemble that of inflammation [15,17]. During the normal course of healing, with no scar tissue formation, it is difficult to determine the presence of inflammation based solely on radiographic findings [15].

All cases demonstrated a reduction in the periapical rarefaction and peripheral osteogenesis, which indicates favorable healing in the presented time periods, which is consistent with findings reported by Leco *et al.* and Le Van C. *et al.* [**Error! Reference source not found.**,19]. The radiographic appearance of periapical bony crypt in case no.1 one year following apicoectomy was consistent with the criteria for complete healing. Due to osseous configuration in case no.2, we expect complete healing after one year.

In Case no.3, the problematic osseous configuration resulted in reduction of the periapical radiolucency due to peripheral bone formation, and persistent central radiolucency. This radiographic appearance was consistent with incomplete healing by scar tissue, according to Andreasen and Rud criteria [17]. It is incomplete healing rather than failure, because the lesion was removed and the infection eradicated.

Conclusion

The results from our limited case series showed that periapical healing following apicoectomy was influenced by the intraoperative osseous configuration. Complete osseous healing was observed in cases with five osseous walls (mesial, distal, coronal, caudal and palatal). The extensive through-and-through defect in case no.3 resulted in incomplete healing with scar formation. Healing by scar tissue may be considered unfavorable, incomplete healing, but it does not indicate unsuccessful treatment.

Conflict of interest statement. None declared.
Written consent of the patients was obtained.

References

1. European Society of Endodontology. Quality guidelines for endodontic treatment: consensus report of the European Society of Endodontology. *Int Endod J* 2006; 39(12): 921-930. doi: 10.1111/j.1365-2591.2006.01180.x.
2. Bergenholtz G, Lekholm U, Milthon R, Heden G, Odesjö B, Engström B. Retreatment of endodontic fillings. Scand J Dent Res 1979; 87(3): 217-224. doi: 10.1111/j.1600-0722.1979.tb00675.x.
3. S. Friedman, C. Mor. The success of endodontic therapy--healing and functionality. *J Calif Dent Assoc* 2004; 32(6): 493-503. PMID: 15344440.
4. Song M, Kim HC, Lee W, Kim E. Analysis of the cause of failure in nonsurgical endodontic treatment by microscopic inspection during endodontic microsurgery. *J Endod* 2011; 37(11): 1516-1519. doi: 10.1016/j.joen.2011.06.032.
5. B. Karabucak, F. Setzer. Criteria for the ideal treatment option for failed endodontics: surgical or nonsurgical? *Compend Contin Educ Dent* 2007; 28(6): 304-310; quiz 311, 332. PMID: 17682612.
6. Karabucak B, Bunes A, Chehoud C, Kohli MR, Setzer F. Prevalence of Apical Periodontitis in Endodontically Treated Premolars and Molars with Untreated Canal: A Cone-beam Computed Tomography Study. *J Endod* 2016; 42(4): 538-541. doi: 10.1016/j.joen.2015.12.026.
7. Wong R. Conventional endodontic failure and retreatment. *Dent Clin North Am* 2004; 48(1): 265-289. doi: 10.1016/j.cden.2003.10.002.
8. Kacarska M. Morphological disposition of apical variations in human maxillary premolars, endodontic and surgical therapeutic challenges. Master's thesis, Skopje, 2003.
9. Kacarska M. Dijagnosis and surgical treatment of periapical inflammatory lesions. Faculty of Dentistry, 2013, ISBN 978-608-4620-06-8.

10. Hupp RJ, Ellis E, Tucker M. Contemporary Oral and Maxillofacial Surgery Sixth Edition Elsevier 2013 ISBN: 978-0-323-09177-0.
11. Molven O, Halse A, Grung B. Incomplete healing (scar tissue) after periapical surgery--radiographic findings 8 to 12 years after treatment. *J Endod* 1996; 22(5): 264-268. doi: 10.1016/s0099-2399(06)80146-9.
12. Bieszczad D, Wichlinski J, Kaczmarzyk T. Factors Affecting the Success of Endodontic Microsurgery: A Cone-Beam Computed Tomography Study. *J Clin Med* 2022; 11(14): 3991. doi: 10.3390/jcm11143991.
13. Saiz-Pardo-Pinos AJ, Manzano-Moreno FJ, Muñoz-Soto E, González-Rodríguez MP, Romero-Olid N, Olmedo-Gaya MV. Analysis of the Prognostic Factors That Influence the Outcome of Periapical Surgery, including Biomimetic Membranes for Tissue Regeneration: A Review. *Biomimetics (Basel)* 2024; 9(5): 258. doi: 10.3390/biomimetics9050258.
14. Rud J, Andreasen JO, Jensen JF. A multivariate analysis of the influence of various factors upon healing after endodontic surgery. *Int J Oral Surg* 1972; 1(5): 258-271. doi: 10.1016/s0300-9785(72)80045-0.
15. Andreasen JO, Rud J. Correlation between histology and radiography in the assessment of healing after endodontic surgery. *Int J Oral Surg* 1972; 1(3): 161-173. doi: 10.1016/s0300-9785(72)80006-1.
16. Shah D, Mital K. The Role of Trypsin:Chymotrypsin in Tissue Repair. *Adv Ther* 2018; 35(1): 31-42. doi: 10.1007/s12325-017-0648-y.
17. Rud J, Andreasen JO, Jensen JE. Radiographic criteria for the assessment of healing after endodontic surgery. *Int J Oral Surg* 1972; 1(4): 195-214. doi: 10.1016/s0300-9785(72)80013-9.
18. Leco Berrocal MI, Martínez González JM, Donado Rodríguez M. Clinical and radiological course in apicoectomies with the Erbium:YAG laser. *Med Oral Patol Oral Cir Bucal* 2007; 12(1): E65-E69. PMID: 17195832
19. Le Van C, Thi Thu HP, Sangvanich P, Chuenchompoonut V, Thunyakitpisal P. Acemannan induces rapid early osseous defect healing after apical surgery: A 12-month follow-up of a randomized controlled trial. *J Dent Sci* 2020; 15(3): 302-309. doi: 10.1016/j.jds.2019.09.012.