Received: October 13, 2026
Accepted: October 28, 2026
Published: November 27, 2026

Acad Med J 2026;6(3):214-218
UDC: 616.594.1-053.2
Case report

GENERALIZED WOOLLY HAIR IN A 3-YEAR-OLD GIRL: A CASE REPORT

Najdova Anita, Dimova Maja, Petkova Ana, Damevska Katerina

University Clinic for Dermatology, Faculty of Medicine,
Ss. Cyril and Methodius University in Skopje, Republic of North Macedonia
e-mail: anitanajdova@yahoo.com

Abstract

Introduction: Woolly hair (WH) is a rare hair shaft disorder characterized by tightly coiled, fine hair. It may occur as an isolated finding or as part of a syndrome, particularly one involving palmoplantar keratoderma and cardiomyopathy.

Case report: We report a 3-year-old girl who developed fine, tightly coiled, fragile scalp hair during early infancy, with persistently limited hair length. There was no family history of similar hair abnormalities or associated systemic disease. Clinical examination and laboratory, cardiologic, and ophthalmologic evaluations revealed no extracutaneous abnormalities. Light microscopy demonstrated focal nodular swellings and variation in hair shaft diameter. The findings supported a clinical diagnosis of generalized woolly hair, without evidence of syndromic involvement at the time of evaluation. Molecular genetic testing was unavailable.

Conclusion: This case highlights the value of combining clinical assessment with hair shaft microscopy and appropriate systemic evaluation. Continued clinical follow-up is warranted because associated systemic manifestations may become apparent later.

Keywords: woolly hair, hair shaft disorder, hair shaft microscopy, pediatric dermatology

Introduction

Woolly hair (WH) is a rare hair shaft disorder that usually becomes apparent at birth or during early childhood[1,2]. It is characterized by unusually tightly coiled, fine hair and should be distinguished from physiologically curly hair. Associated shaft abnormalities may include reduced caliber, an elliptical cross-section, and irregular twisting, which can contribute to fragility and breakage[1,2]. Clinically, the hair may appear dry, short, and relatively hypopigmented. Limited hair length may reflect recurrent breakage rather than reduced follicular growth.

Woolly hair has traditionally been classified into three forms: autosomal dominant hereditary woolly hair, autosomal recessive familial woolly hair, and localized woolly hair nevus[3]. Generalized woolly hair may occur as an isolated disorder or as part of a syndrome. The inheritance pattern alone does not reliably distinguish non-syndromic from syndromic disease; assessment for associated cutaneous and systemic findings is therefore important[2,3].

Molecular studies have identified pathogenic variants in genes involved in hair shaft formation and cell adhesion in both isolated and syndromic woolly hair[1,4]. Variants in *LPAR6* (formerly *P2RY5*) and *LIPH* are established causes of autosomal recessive woolly hair, with or without hypotrichosis[4,5]. Syndromic forms include Naxos and Carvajal disease, in which woolly hair may accompany palmoplantar keratoderma and cardiomyopathy associated with defects in desmosomal proteins[6,7].

Woolly hair nevus is a localized form characterized by a well-demarcated area of tightly curled hair that differs from the surrounding scalp hair in texture and sometimes pigmentation[8]. It usually occurs as an isolated finding, although associated epidermal nevi have been reported. Distinguishing localized from generalized involvement helps guide the clinical assessment.

Clinical assessment should look for associated findings, particularly palmoplantar keratoderma, cardiac abnormalities, and other features suggestive of syndromic disease[4,6,7]. In cardiocutaneous syndromes, hair changes may precede clinically apparent cardiac involvement. The absence of systemic abnormalities at the initial assessment therefore supports an apparently isolated presentation but does not exclude manifestations developing later[6,7]. Here, we report generalized woolly hair in a 3-year-old girl, without a family history of similar hair abnormalities or evidence of systemic involvement at the time of evaluation.

Case report

A 3-year-old girl of Romani ethnicity (Fitzpatrick skin phototype IV) was referred to the University Clinic for Dermatology in Skopje for evaluation of tightly coiled, fragile scalp hair and persistently limited hair length.

According to her parents, she was born at term after an uncomplicated pregnancy and delivery, with normal hair density and texture at birth. At approximately three months of age, following scalp shaving as part of a customary cultural practice, the regrowing hair was noticed to be finer, tightly coiled, and fragile. By the age of three years, hair length did not exceed approximately 10 cm.

The parents reported no family history of similar hair abnormalities, hypotrichosis, cardiomyopathy, palmoplantar keratoderma, or other hereditary dermatologic conditions. No parental consanguinity was reported.

Physical examination showed a well-appearing child with normal growth parameters and age-appropriate psychomotor development. Scalp involvement was diffuse, with the changes most pronounced over the parietal, temporal, and occipital regions. The hair was tightly coiled, fine, and fragile, with a dry, frizzy, and matte appearance (Figure 1). No scarring alopecia, perifollicular erythema, scaling, or other inflammatory scalp changes were observed.



Fig. 1. Posterior view of the scalp showing short, curly hair of uneven length with a frizzy appearance

Examination of the eyebrows, eyelashes, body hair, nails, dentition, oral mucosa, and skin revealed no additional abnormalities. There was no palmoplantar keratoderma, follicular hyperkeratosis, ichthyosis, milia, or abnormal skin pigmentation. No other clinical features suggestive of ectodermal dysplasia or a cardiocutaneous syndrome were identified.

Complete blood count, serum biochemistry, inflammatory markers, and thyroid function tests were within normal limits. Cardiac evaluation, including electrocardiography and transthoracic echocardiography, revealed no abnormalities. Abdominal ultrasonography and ophthalmologic examination were also unremarkable.

Light microscopy of the hair shafts showed focal nodular swellings and variation in shaft diameter (Figure 2). No features characteristic of monilethrix, pili torti, trichorrhexis invaginata, or trichorrhexis nodosa were observed in the examined samples.

Molecular genetic testing was considered to investigate the underlying genetic cause but was not performed because of limited access to specialized testing.

The clinical and microscopic findings supported a clinical diagnosis of generalized woolly hair, without evidence of syndromic involvement at the time of evaluation. The parents were advised on gentle hair care and avoidance of practices that could increase hair shaft damage. The importance of periodic clinical follow-up to assess for emerging cutaneous or systemic findings was explained. Follow-up data were not available at the time of manuscript preparation.

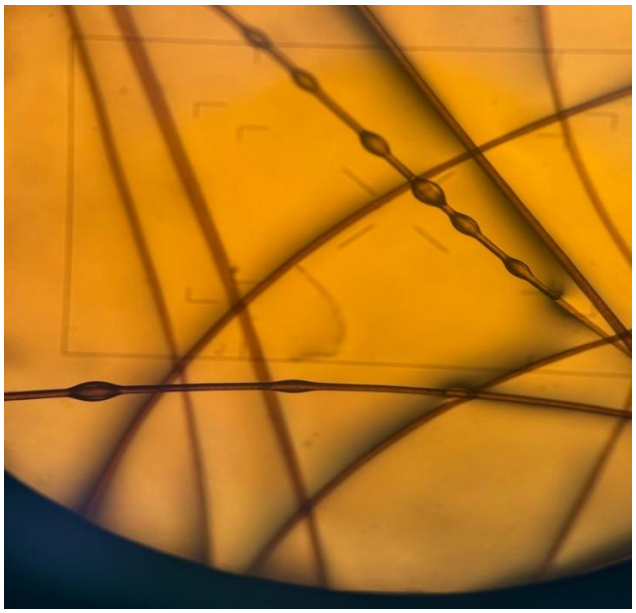

Fig. 2. Light microscopy showing multiple focal spindle-shaped swellings along the hair shafts

Discussion

Woolly hair encompasses a clinically and genetically heterogeneous group of hair disorders, ranging from isolated hair involvement to syndromic forms associated with extracutaneous abnormalities[1,2,4]. In this patient, the early onset, diffuse distribution, and altered hair texture supported a clinical diagnosis of generalized woolly hair. No associated cutaneous or systemic abnormalities were identified at the initial evaluation. However, this finding should be interpreted in the context of the patient's young age and the absence of molecular genetic testing[6,7].

According to the parents, the altered hair texture became apparent during regrowth after scalp shaving at approximately three months of age. This temporal association does not establish a causal relationship between shaving and the hair abnormality. Given the early onset,

an underlying developmental hair shaft disorder was considered, although its genetic basis could not be investigated.

Light microscopy revealed focal nodular swellings and variation in hair shaft diameter. These findings document an alteration in shaft morphology but are not specific to woolly hair. Their diagnostic relevance should therefore be considered together with the clinical appearance and distribution of the hair changes[2,9].

Pathogenic variants in *LPAR6* and *LIPH* are established causes of autosomal recessive woolly hair, with or without hypotrichosis[4,5]. Variants affecting desmosomal proteins are implicated in cardiocutaneous syndromes associated with woolly hair[6,7]. In this patient, the absence of a family history does not exclude a genetic cause. As molecular testing was unavailable, neither the underlying pathogenic variant nor the mode of inheritance could be determined.

The differential diagnosis includes other hair shaft disorders, such as monilethrix, pili torti, trichorrhexis invaginata, and trichorrhexis nodosa[2,9]. Microscopic assessment should distinguish regular alternating nodes and constrictions, axial twisting, shaft invagination, and nodal fraying or fracture, respectively[9]. In this case, the focal swellings were described without assigning a specific additional hair shaft disorder. The diagnosis of woolly hair was based primarily on the clinical phenotype.

The absence of palmoplantar keratoderma and the normal initial cardiac evaluation supported an apparently isolated presentation at the time of assessment. However, cardiac manifestations of inherited cardiocutaneous syndromes may become apparent later, so a normal evaluation at three years of age does not definitively exclude syndromic disease[6,7]. Continued clinical follow-up is therefore appropriate, with further cardiac assessment guided by specialist advice and any emerging symptoms or signs.

Management focused on gentle hair care and minimizing mechanical damage. The parents were advised to avoid vigorous brushing, excessive heat, and harsh chemical treatments that could worsen hair shaft fragility[2,9]. Counseling addressed the appearance of the hair and the limitations of the available diagnostic assessment. Follow-up was recommended to monitor the hair changes and assess for any emerging associated findings.

Conclusion

Generalized woolly hair should be considered in children presenting with unusually tightly curled hair, fragility, and persistently limited hair length. This case illustrates the value of combining clinical assessment with hair shaft microscopy and evaluation for associated systemic findings. The absence of extracutaneous abnormalities at the initial assessment supports an apparently isolated presentation, while continued follow-up remains important.

Conflict of interest statement. None declared.
Written informed consent was obtained from the patient's parent

References

1. Shimomura Y, Christiano AM. Biology and genetics of hair. *Annu Rev Genomics Hum Genet* 2010; 11: 109-132. doi:10.1146/annurev-genom-021610-131501.
2. Shimomura Y. Congenital hair loss disorders: rare, but not too rare. *J Dermatol* 2012; 39(1): 3-10. doi:10.1111/j.1346-8138.2011.01395.x
3. Hutchinson PE, Cairns RJ, Wells RS. Woolly hair. Clinical and general aspects. *Trans St Johns Hosp Dermatol Soc* 1974; 60(2): 160-177. PMID: 4467886.
4. Kurban M, Wajid M, Shimomura Y, Christiano AM. Mutations in LPAR6/P2RY5 and LIPH are associated with woolly hair and/or hypotrichosis. *J Eur Acad Dermatol Venereol* 2013; 27(5): 545-549. doi: 10.1111/j.1468-3083.2012.04472.x.

5. Shimomura Y, Wajid M, Petukhova L, Shapiro L, Christiano AM. Mutations in the lipase H gene underlie autosomal recessive woolly hair/hypotrichosis. *J Invest Dermatol* 2009; 129(3): 622-628. doi: 10.1038/jid.2008.290.
6. McGrath JA. Inherited disorders of desmosomes. *Australas J Dermatol* 2005; 46(4): 221-229. doi: 10.1111/j.1440-0960.2005.00188.x.
7. Protonotarios N, Tsatsopoulou A. Naxos disease: cardiocutaneous syndrome due to cell adhesion defect. *Orphanet J Rare Dis* 2006; 1: 4. doi: 10.1186/1750-1172-1-4.
8. Post CF. Woolly hair nevus; report of a case. *AMA Arch Derm* 1958; 78(4): 488-489. doi: 10.1001/archderm.1958.01560100064010.
9. Itin PH, Fistarol SK. Hair shaft abnormalities--clues to diagnosis and treatment. *Dermatology* 2005; 211(1): 63-71. doi: 10.1159/000085582.