Received: October 22, 2026
Accepted: November 6, 2026
Published: November 27, 2026

Acad Med J 2026;6(3):187-196
UDC:617.76-02:616.21-002,,2020/2025"
Original article

ORBITAL COMPLICATIONS OF RHINOSINUSITIS: CLINICAL PRESENTATION AND MANAGEMENT

Marolov Marjan[1], Debreshlioska Angela[2], Dokoska Marija[1], Netkovski Jane[1]

[1]University Clinic for Ear, Nose and Throat, Faculty of Medicine,
Ss. Cyril and Methodius University in Skopje, Republic of North Macedonia
[2]University Clinic for Pulmonology and Allergology, Faculty of Medicine,
Ss. Cyril and Methodius University in Skopje, Republic of North Macedonia
e-mail: marjanmarolov@gmail.com

Abstract

Introduction: This study describes the clinical presentation, treatment and discharge outcomes of patients hospitalized with orbital complications of rhinosinusitis.

Materials and methods: A single-center retrospective observational study included 44 consecutive patients treated from January 2020 to September 2025. Data were obtained from hospital records, computed tomography reports and operative findings. Frequencies, percentages and selected Wilson 95% confidence intervals were calculated. An exploratory two-sided Fisher exact test examined documented subperiosteal abscess and surgery in patients with exclusively orbital complications.

Results: The series included 23 children and 21 adults; 24 patients were male. Forty patients had exclusively orbital complications; two had additional intracranial suppurative complications and two had cavernous sinus thrombosis. Anterior ethmoid involvement occurred in 41/44 (93.2%). All patients received intravenous antibiotics; 24/44 underwent surgery (54.5%). Among the 40 exclusively orbital cases, 13 had subperiosteal abscess, 24 postseptal cellulitis and three preseptal cellulitis. Surgery was performed in 13/13 abscess cases *versus* 7/27 other cases ($p < 0.001$). Eight patients underwent frontal trephination. Forty patients achieved complete orbital resolution without residual visual impairment at discharge. Two required subsequent neurosurgical care; one underwent neurosurgical reoperation. Both patients with cavernous sinus thrombosis died.

Conclusion: Treatment included intravenous antibiotics alone or in combination with surgery, depending on the clinical findings. All patients with a documented subperiosteal abscess underwent surgery, but this finding alone does not establish the abscess as an independent predictor of surgical treatment. Unfavorable outcomes occurred in patients with associated intracranial complications or cavernous sinus thrombosis.

Keywords: sinusitis; orbital cellulitis; abscess; endoscopy; cavernous sinus thrombosis

Introduction

Rhinosinusitis may extend beyond the paranasal sinuses and involve orbital, intracranial or bony structures. Although these complications represent a selected minority of rhinosinusitis presentations, they require coordinated diagnostic assessment and treatment. The European Position Paper on Rhinosinusitis and Nasal Polyps provides the broader clinical framework for evaluating acute disease and chronic disease with acute deterioration[1].

Orbital involvement encompasses preseptal and postseptal inflammation, subperiosteal abscess and orbital abscess. The Chandler classification remains a widely used reference for describing these conditions and cavernous sinus thrombosis[2]. Clinically, the orbital findings and any associated intracranial extension must be considered together. Classification provides a common language but does not, by itself, describe every factor affecting treatment.

Published institutional series describe heterogeneous populations and management pathways. Sansa-Perna *et al.,* reported 21 patients with orbital complications, including children and adults[3]. Asiri *et al*., described 43 patients with orbital, intracranial or combined complications [4]. Adult and pediatric series further illustrate the importance of age, disease severity and the local clinical setting when interpreting treatment patterns[5,6]. Recent reports have also examined the relationship between clinical or radiological findings and surgery[7,8].

A focused description of routine practice can document the clinical spectrum and the procedures used without requiring a comprehensive anatomical analysis. This study aimed to describe the clinical presentation, sinus involvement, complication categories, treatment and recorded discharge outcomes of consecutive patients hospitalized with orbital complications of rhinosinusitis at a university ENT clinic. The association between documented subperiosteal abscess and surgery was examined as an exploratory analysis in the subgroup with exclusively orbital complications.

Materials and methods

Study design and setting

This single-center retrospective observational study comprised a descriptive clinical case series with one exploratory subgroup comparison. All 44 consecutive, distinct patients hospitalized at the University Clinic for Ear, Nose and Throat in Skopje, North Macedonia, with orbital complications of rhinosinusitis between 1 January 2020 and 30 September 2025 were included. Repeat admissions and repeat operations were not counted as additional patients. Reporting was structured with reference to the STROBE recommendations where applicable[9].

Patients and data sources

Patients with acute rhinosinusitis or an acute exacerbation of chronic rhinosinusitis were eligible. The two underlying disease categories were not separately quantified in this analysis. Associated intracranial suppurative complications and cavernous sinus thrombosis did not lead to exclusion. Clinical information was abstracted from hospital histories, discharge documentation, radiology reports and operative records. All patients underwent computed tomography during the episode and ophthalmological assessment during hospitalization. The present analysis used aggregated counts and did not reconstruct a complete patient-level dataset.

Patients were categorized as pediatric (<18 years) or adult (≥18 years). Age group and sex were summarized descriptively; no age- or sex-specific hypothesis tests were performed.

Variables and complication categories

Recorded variables included involvement of the maxillary, anterior ethmoid, posterior ethmoid, sphenoid and frontal sinuses; clinical symptoms and signs on admission; duration of sinus symptoms before admission; complication categories; treatment; operative procedures; and recorded outcomes. Fever represented its documented occurrence during the illness rather than exclusively on admission. Sinus involvement and clinical findings were not mutually exclusive. Duration of sinus symptoms was grouped as 1-3, 4-7 or ≥8 days; the interval from admission to surgery was not analyzed.

For the overall complication distribution, mutually exclusive groups were defined as exclusively orbital complications; orbital complications with additional intracranial suppurative

involvement; and orbital complications with cavernous sinus thrombosis. Cavernous sinus thrombosis was tabulated separately to preserve this distinction. Pott's puffy tumor was recorded as an additional, overlapping complication rather than a fourth exclusive group.

Within the 40 exclusively orbital cases, the documented categories were preseptal cellulitis, postseptal cellulitis without a documented abscess, and subperiosteal abscess. These were based on available CT reports and/or operative findings, rather than a standardized independent rereading of the initial CT images. Subperiosteal abscess was supported by radiology and/or operative documentation. The precise orbital subtype was not established in the aggregated data for the four combined cases; these patients were not assigned to an assumed subtype and were excluded only from the abscess–surgery comparison. A complete initial Chandler stage distribution for all 44 patients was therefore not reconstructed.

Preseptal cellulitis denoted inflammation confined to the tissues anterior to the orbital septum, without documented postseptal extension. Postseptal cellulitis denoted inflammation within the orbit, posterior to the septum, without a documented localized abscess. Subperiosteal abscess denoted a localized collection between the orbital bony wall and the periorbita, documented in a CT report and/or confirmed by operative drainage[2]. These definitions describe the recorded diagnostic categories and do not imply that every abscess was identified on the initial CT report.

Treatment and operative procedures

All patients received intravenous antibiotics. Twenty patients were managed medically without surgery for the episode; 24 underwent surgery in addition to medical treatment. Management was individualized in routine clinical practice, rather than assigned by a research protocol. The available aggregate data did not permit quantitative comparison of antibiotic regimens, analysis of treatment timing or assessment of the reasons for every individual operative decision.

The most commonly used initial intravenous antibiotic regimen was ceftriaxone combined with clindamycin. Meropenem was used as a second-line agent, and metronidazole was added in selected cases. Regimen-specific patient counts, doses and treatment durations were not available for quantitative analysis.

Systemic corticosteroids, including dexamethasone or methylprednisolone, were routinely administered during the first days of hospitalization. Intranasal corticosteroids were used in most patients, with oral antihistamines in selected cases. Topical nasal decongestants were also routinely used. Selected patients underwent application of adrenaline-soaked nasal pledgets and local nasal suction once or twice daily. These treatments describe routine practice during the study period; their individual contributions to the clinical outcomes were not assessed.

The principal clinical indications for surgery were a documented abscess, an inadequate response to antibiotic treatment, or worsening orbital or ophthalmological findings. The timing and extent of surgery were determined by the treating clinicians on an individual basis; no uniform research-defined time threshold was applied.

Surgical categories represented mutually exclusive patient pathways. Endoscopic sinus surgery (ESS) alone was distinguished from ESS with endoscopic orbital decompression, frontal sinus trephination, or both. The seven patients in the exclusively orbital ESS-alone category had cellulitis, without documented orbital pus or orbital drainage. Endoscopic orbital decompression involved removal of part of the lamina papyracea and incision of the periorbita to allow orbital fat to prolapse medially into the ethmoid cavity.

Frontal trephination involved a small bony opening of approximately 5–6 mm for aspiration and irrigation. It was used as an adjunct to ESS when complex frontal recess anatomy was encountered. A catheter was passed through the frontal drainage pathway into the nasal cavity and retained for 7-10 days for drainage and irrigation. Eight patients underwent this

procedure, including two with bilateral trephination. Detailed anatomical characterization was outside the scope of the present report. Adjunctive minitrephination has previously been described in the management of complex frontal sinus disease[10].

Three patients underwent transmaxillary drainage of a subperiosteal orbital abscess through a Caldwell-Luc approach, either alone or combined with ESS. This procedure was distinguished from endoscopic orbital decompression. Two patients with intracranial suppurative involvement underwent ESS at the University ENT Clinic followed several days later by craniotomy at neurosurgery; these were staged procedures. The two patients with cavernous sinus thrombosis underwent ESS without neurosurgical intervention. In one of these patients, limited ESS was performed under analgosedation because general anesthesia with orotracheal intubation was not feasible.

Selection of the transmaxillary approach reflected the operating surgeon's assessment, familiarity with the approach and perceived anatomical complexity, rather than a uniform study-defined indication. These cases describe the treatment selected in routine practice during the study period and do not establish a comparative advantage over endoscopic drainage.

Outcomes

Complete clinical resolution at ENT discharge was established from the documented clinical assessment and discharge ophthalmological examination. It required resolution of eyelid/periorbital edema and erythema, absence of pain and chemosis, normal ocular motility, absence of diplopia and proptosis, and normal visual function or return to the pre-episode level, without residual visual impairment attributable to the episode. Continued neurosurgical treatment and death during the documented clinical episode were recorded separately. A neurosurgical reoperation was counted as an additional event in the same patient, not as a new case. Long-term recovery, recurrence and a uniform 30-day outcome were not assessed; the eventual outcomes after continued neurosurgical care were unavailable.

Statistical analysis

Categorical variables were summarized as counts and percentages, with denominators stated for each table. The analysis of overall clinical findings included 44 patients; the analysis of orbital subtypes included the 40 exclusively orbital cases, and the analysis of operative pathways included the 24 surgical patients. Selected proportions were accompanied by two-sided 95% Wilson score confidence intervals. No means, medians or tests for continuous variables were calculated from grouped symptom-duration data.

One exploratory two-sided Fisher exact test compared the proportion undergoing surgery among patients with documented subperiosteal abscess and those classified as cellulitis in the exclusively orbital subgroup. The verified 2×2 table comprised 13 surgical and zero medical-only abscess cases *versus* seven surgical and 20 medical-only cellulitis cases. The absolute difference in observed surgery proportions was accompanied by a Newcombe confidence interval based on Wilson intervals. The test used a nominal significance threshold of 0.05. It was not a prespecified predictive analysis. No multivariable adjustment or other hypothesis tests were performed because linked patient-level covariates were unavailable and several groups were small. Calculations used Python 3.12.14 with exact hypergeometric probabilities and standard score-interval formulas.

Results

Clinical presentation and sinus involvement

The series included 44 distinct patients: 23 children aged <18 years (52.3%) and 21 adults aged ≥18 years (47.7%). There were 24 male (54.5%) and 20 female patients (45.5%). Anterior ethmoid involvement was documented in 41 patients (93.2%), followed by maxillary

involvement in 39 (88.6%), posterior ethmoid involvement in 32(72.7%), frontal involvement in 28(63.6%) and sphenoid involvement in 13(29.5%) patients. Multiple sinuses could be involved in the same patient.

Eyelid edema was the most frequent recorded presenting finding (36/44, 81.8%). Nasal discharge was recorded in 26 patients (59.1%), headache in 24 (54.5%) and nasal obstruction in 21(47.7%). Fever during the illness was observed in 24 (54.5%). Twenty-two patients (50.0%) had experienced sinus symptoms for 1-3 days before admission, 14 (31.8%) for 4-7 days and eight (18.2%) for ≥8 days (Table 1).

Table 1. Clinical findings and sinus involvement in all 44 patients

Domain	Finding	n	%
Sinus involvement	Maxillary	39	88.6
Sinus involvement	Anterior ethmoid	41	93.2
Sinus involvement	Posterior ethmoid	32	72.7
Sinus involvement	Sphenoid	13	29.5
Sinus involvement	Frontal	28	63.6
Clinical finding	Eyelid edema	36	81.8
Clinical finding	Headache	24	54.5
Clinical finding	Fever during illness	24	54.5
Clinical finding	Eye discharge	6	13.6
Clinical finding	Nasal discharge	26	59.1
Clinical finding	Nasal obstruction	21	47.7
Clinical finding	Chemosis	8	18.2
Clinical finding	Frontal swelling / Pott's puffy tumor	3	6.8
Clinical finding	Buccal swelling	2	4.5
Clinical finding	Seizures	2	4.5
Symptoms before admission	1–3 days	22	50.0
Symptoms before admission	4–7 days	14	31.8
Symptoms before admission	≥8 days	8	18.2

Denominator: 44 patients. Sinus involvement and clinical findings may overlap. Findings refer to admission except fever, which was recorded during the illness. Duration refers to sinus symptoms before hospital admission.

Complication spectrum

Forty patients (90.9%) had exclusively orbital complications, two (4.5%) had orbital complications with additional intracranial suppurative involvement, and two (4.5%) had orbital complications with cavernous sinus thrombosis. The two other intracranial presentations were subdural empyema alone and subdural empyema with meningitis. Pott's puffy tumor was documented in three patients (6.8%) as an associated complication (Table 2).

Among the 40 exclusively orbital cases, three (7.5%) were classified as preseptal cellulitis, 24(60.0%) as postseptal cellulitis and 13(32.5%; 95% CI 20.1-48.0%) as subperiosteal abscess. The orbital subtype was unavailable for the four combined cases, and therefore the total number of abscesses across all 44 patients could not be determined. The 13 documented abscess cases represented 29.5% of the complete series but should not be interpreted as an exhaustive abscess prevalence in all 44 patients.

Table 2. Complication categories and documented orbital subtypes

Category	n	Total N	%
Exclusively orbital complications	40	44	90.9
Orbital plus other intracranial suppurative complications	2	44	4.5
Orbital plus cavernous sinus thrombosis	2	44	4.5
Associated Pott's puffy tumor	3	44	6.8
Preseptal cellulitis in exclusively orbital cases	3	40	7.5
Postseptal cellulitis in exclusively orbital cases	24	40	60.0
Subperiosteal abscess in exclusively orbital cases	13	40	32.5

The first three rows are mutually exclusive and sum to 44. Pott's puffy tumor is an overlapping finding. The last three rows sum to the 40 exclusively orbital cases and use radiological and/or operative documentation. The orbital subtype of the four combined cases was not determined. Other intracranial complications were subdural empyema (n = 1) and subdural empyema with meningitis (n = 1). Percentages may differ from 100% because of rounding.

Treatment

All 44 patients received intravenous antibiotics. Medical treatment alone was used in 20 (45.5%; 95% CI 31.7–59.9%) and surgery in addition to antibiotics in 24 (54.5%; 95% CI 40.1–68.3%). Treatment distribution by complication group is shown in Figure 1.

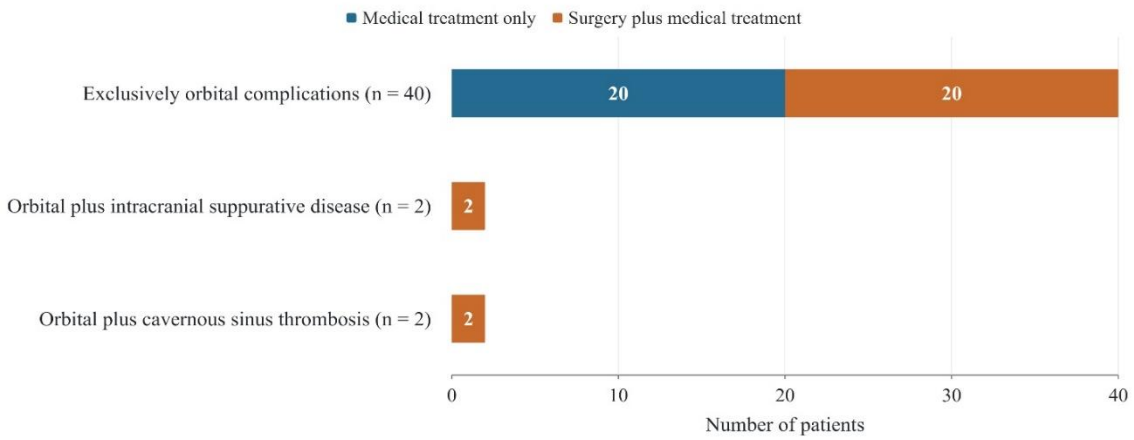

Fig. 1. Treatment by complication group

Absolute numbers of patients managed with medical treatment alone or surgery in addition to medical treatment. All 44 patients received intravenous antibiotics. Bars share a common zero-based scale; labels inside the bars show patient counts. The figure describes observed management and does not compare treatment effectiveness.

Among the 24 surgical patients, seven underwent ESS alone for exclusively orbital disease; two ESS with endoscopic orbital decompression; six ESS with frontal trephination; two ESS with both orbital decompression and frontal trephination; one transmaxillary abscess drainage through a Caldwell–Luc approach alone; and two ESS combined with transmaxillary abscess drainage. Two additional patients with cavernous sinus thrombosis underwent ESS, while two with intracranial suppurative complications underwent ESS followed by neurosurgical craniotomy. Thus, eight patients underwent adjunctive frontal trephination, four endoscopic orbital decompression, and three transmaxillary abscess drainage (Table 3). These totals describe overlapping components of the mutually exclusive pathways.

Table 3. Mutually exclusive operative pathways among 24 surgical patients

Operative pathway	n	% of 24
ESS alone for exclusively orbital cellulitis	7	29.2
ESS with endoscopic orbital decompression	2	8.3
ESS with frontal sinus trephination	6	25.0
ESS with endoscopic orbital decompression and frontal sinus trephination	2	8.3
Caldwell–Luc approach with transmaxillary subperiosteal abscess drainage	1	4.2
ESS with Caldwell–Luc approach and transmaxillary subperiosteal abscess drainage	2	8.3
ESS in patients with cavernous sinus thrombosis, without neurosurgery	2	8.3
ESS followed by staged neurosurgical craniotomy	2	8.3
Total	24	100.0

Each patient appears once. ESS: endoscopic sinus surgery. Endoscopic orbital decompression included periorbital incision; transmaxillary abscess drainage is tabulated separately. Eight patients underwent frontal trephination, bilateral in two; a catheter was retained for 7–10 days. Craniotomies were performed later at neurosurgery. One of these patients underwent a further neurosurgical ontervention, without being counted again. Rounding may affect the sum of percentages.

Recorded outcomes

Complete orbital resolution without residual visual impairment at discharge was recorded in 40/44 patients (90.9%; 95% CI 78.8–96.4%). Two patients continued treatment under neurosurgery after the staged procedures; one of these children underwent an additional neurosurgical operation. Both patients with cavernous sinus thrombosis died, corresponding to 2/44 recorded deaths (4.5%; 95% CI 1.3-15.1%). Their serious concomitant clinical conditions precluded attributing the deaths solely to the orbital infection or the selected surgical approach. No longer-term outcome was assigned to the two patients who continued neurosurgical treatment (Table 4).

Table 4. Treatment and recorded outcomes in all 44 patients

Measure	n/N	%	95% CI
Intravenous antibiotic treatment	44/44	100.0	92.0-100.0
Medical treatment without surgery	20/44	45.5	31.7-59.9
Surgery in addition to medical treatment	24/44	54.5	40.1-68.3
Complete orbital resolution without residual visual impairment at discharge	40/44	90.9	78.8-96.4
Continued neurosurgical care	2/44	4.5	1.3-15.1
Recorded deaths	2/44	4.5	1.3-15.1

CI: Wilson score confidence interval, expressed as a percentage. The last three rows are the mutually exclusive recorded outcome categories. Both deaths occurred in patients with cavernous sinus thrombosis. One of the two patients continuing neurosurgical care underwent reoperation. The eventual outcomes after continued neurosurgical care and uniform 30-day outcomes were not available.

Exploratory abscess and surgery comparison

All 13 patients with documented subperiosteal abscess in the exclusively orbital group

Table 5. Exploratory comparison in the 40 exclusively orbital cases

Documented category	Surgery	Medical only	Total	Surgery %
Subperiosteal abscess	13	0	13	100.0
Cellulitis without documented abscess	7	20	27	25.9
Total	20	20	40	50.0

Two-sided Fisher exact $p<0.001$. Absolute difference in observed surgery proportions: 74.1 percentage points (95% Newcombe CI 44.5-86.8). Wilson 95% CI for surgery: 77.2-100.0% in abscess cases and 13.2-44.7% in cellulitis cases. Cellulitis includes three preseptal and 24 postseptal cases. The four combined cases are excluded from this comparison because their orbital subtype was not established. Abscess classification used CT and/or operative records; the comparison is subject to clinical treatment selection and differential ascertainment. It does not estimate independent prediction or treatment efficacy.

underwent surgery, compared with 7/27 patients classified as cellulitis (100.0% *versus* 25.9%; two-sided Fisher exact p<0.001). The absolute difference in observed surgery proportions was 74.1 percentage points (95% CI 44.5-86.8; Table 5). This was an association with recorded management. It was not an estimate of treatment benefit or an independent preoperative prediction.

Discussion

This series describes 44 consecutive patients with orbital complications of rhinosinusitis managed over five years and nine months at one university ENT clinic. The main observations were frequent anterior ethmoid and maxillary involvement, a broad spectrum from cellulitis to combined intracranial disease, and substantial use of both medical and surgical treatment. Forty patients had complete orbital resolution at discharge, while the four combined cases required further neurosurgical care or had a fatal outcome.

The scope of this series is comparable to institutional reports that combine clinical presentation, complication categories and management. Asiri *et al.,* included 43 patients with orbital, intracranial or combined complications and described sinus involvement, symptoms, treatment and prognosis[4]. Their broader case definition included isolated intracranial disease, whereas every patient in the present series had orbital involvement. This difference in the source population matters when comparing percentages of complications or procedures. Our figures describe hospitalized patients with complications and cannot estimate the incidence of complications among all patients with rhinosinusitis.

The high frequency of ethmoid involvement is consistent with the anatomical proximity of the ethmoid labyrinth to the medial orbital wall. However, this aggregate analysis does not show that involvement of any particular sinus independently increased the probability of abscess, surgery or death. Sinus involvement could coexist, and the necessary patient-level cross-tabulations were unavailable. The findings should therefore be interpreted as the distribution of radiological disease in the series.

Surgery was used in just over half of the complete series and in half of the exclusively orbital subgroup. Sansa-Perna *et al.,* described both medical and operative management in a smaller mixed-age series[3]. Fernandes *et al.,* reported 28 adults with acute or chronic rhinosinusitis, with 46.4% undergoing surgery[5]. In the pediatric series of Trivić *et al.*, age and initial complication severity were important in the treatment pattern[6]. These reports provide context, but their different age composition, referral patterns and definitions prevent interpreting differences in surgery percentages as differences in effectiveness. The present sample included both children and adults in similar numbers, but the aggregate data did not permit age-specific comparisons of severity or treatment.

The association between documented abscess and surgery was pronounced in the exclusively orbital subgroup. Nevertheless, the decision to operate was clinically selected, and abscess status was sometimes established from the operative record. Consequently, confounding by indication and differential ascertainment can both contribute to the association. The exact test quantifies the observed separation between the recorded categories; it does not validate an independent predictor. More detailed studies have examined radiological dimensions, clinical signs and classification categories in relation to treatment[7,8]. The current series does not contain the linked baseline measurements needed to reproduce those analyses.

The operative spectrum illustrates several ways of obtaining sinus source control and managing orbital involvement. Endoscopic sinus surgery alone was distinguished from drainage of an orbital collection and from decompression involving periorbital incision. This distinction avoids treating every endoscopic operation as orbital drainage. Adjunctive frontal trephination was used in eight patients when frontal recess anatomy was considered difficult intraoperatively. Cohen and Wang described minitrephination as an adjunct for frontal recess

identification and irrigation in complex frontal disease[10]. The study supports the procedural context, but neither their findings nor our descriptive counts establish that trephination is superior to an endoscopic alternative in complicated infection. Anatomical determinants and longer-term frontal drainage outcomes require a separate analysis.

Combined disease involved only four patients, but these cases accounted for the unfavorable recorded outcome categories. Both patients with cavernous sinus thrombosis died. Because there were only two such cases and serious concomitant clinical conditions were present, no reliable mortality model or comparison between procedures is possible. The two patients with intracranial suppurative involvement underwent ESS and later craniotomy, with an additional neurosurgical operation in one child. These staged procedures reflect care across specialties and should not be reported as simultaneous combined surgery. Continued neurosurgical treatment is also different from a documented final treatment failure, as the eventual outcomes were not available.

The study has several limitations. It is retrospective and reflects the practice of a single referral clinic. Analysis used aggregated data rather than a complete linked dataset, preventing adjustment for age, comorbidity, initial visual function, disease severity and treatment timing. Documentation-based abscess classification was not identical to a blinded assessment of baseline CT, and the orbital subtype of the four combined cases was not established. The study included both acute disease and acute exacerbations of chronic rhinosinusitis without separate subgroup analysis. Antibiotic regimens and adjunctive treatments were described without regimen-specific counts, doses or durations, and their associations with outcomes were not analyzed. Length of stay and long-term outcomes were not analyzed. These limitations restrict causal interpretation, treatment comparisons and generalization beyond similar hospitalized populations.

Conclusion

In this retrospective series of 44 hospitalized patients with orbital complications of rhinosinusitis, treatment ranged from intravenous antibiotics alone to endoscopic, external, combined and staged surgical procedures. Most patients had complete orbital resolution at discharge 40/44(90.9%), while combined intracranial and cavernous sinus involvement accounted for the unfavorable recorded outcomes. Documented subperiosteal abscess was associated with surgery in the exclusively orbital subgroup, but the observational and documentation-based design does not establish independent prediction or comparative treatment efficacy.

Conflict of interest statement. None declared.

References

1. Fokkens WJ, Lund VJ, Hopkins C, Hellings PW, Kern R, Reitsma S, *et al*. European Position Paper on Rhinosinusitis and Nasal Polyps 2020. Rhinology 2020; 58(Suppl S29): 1-464. doi: 10.4193/Rhin20.600.
2. Chandler JR, Langenbrunner DJ, Stevens ER. The pathogenesis of orbital complications in acute sinusitis. *Laryngoscope* 1970; 80(9): 1414-1428. doi: 10.1288/00005537-197009000-00007.
3. Sansa-Perna A, Gras-Cabrerizo JR, Montserrat-Gili JR, Rodríguez-Álvarez F, Massegur-Solench H, Casasayas-Plass M. Our experience in the management of orbital complications in acute rhinosinusitis. *Acta Otorrinolaringol Esp (Engl Ed)* 2020; 71(5): 296-302. doi: 10.1016/j.otorri.2019.11.005.

4. Asiri MA, Almusallam MH, Almashari Y, Allarakia Y, Alhedaithy RA. Orbital and intracranial complications of acute rhinosinusitis in a tertiary center, Saudi Arabia. *Cureus* 2023; 15(8): e42866. doi: 10.7759/cureus.42866.
5. Fernandes JA, Andrade A, Valente P, Vaz R. Orbital complications of rhinosinusitis in adults: a 10-year retrospective cohort study. *Cureus* 2025; 17(6): e86868. doi: 10.7759/cureus.86868.
6. Trivić A, Cevik M, Folić M, Krejovic-Trivić S, Rubino S, Micić J, *et al*. Management of orbital complications of acute rhinosinusitis in pediatric patients: a 15-year single-center experience. *Pediatr Infect Dis J* 2019; 38(10): 994-998. doi: 10.1097/INF.0000000000002414.
7. Turgut Semerci H, Bahadır O, Çobanoğlu HB. When should we perform surgery in orbital complication due to rhinosinusitis? *Northwestern Med J* 2026; 6(2): 131-143. doi: 10.54307/NWMJ.2026.164.
8. Vinciguerra A, Rampinelli V, Turri-Zanoni M, Ferrari M, Valentini M, Arosio AD, *et al*. Orbital complications of acute rhinosinusitis in adulthood: predictors of outcome and management. *Laryngoscope* 2026; 136(5): 2073-2081. doi:10.1002/lary.70309.
9. von Elm E, Altman DG, Egger M, Pocock SJ, Gøtzsche PC, Vandenbroucke JP. The Strengthening the Reporting of Observational Studies in Epidemiology (STROBE) statement: guidelines for reporting observational studies. *PLoS Med* 2007; 4(10): e296. doi: 10.1371/journal.pmed.0040296.
10. Cohen AN, Wang MB. Minitrephination as an adjunctive measure in the endoscopic management of complex frontal sinus disease. *Am J Rhinol* 2007; 21(5): 629-636. doi: 10.2500/ajr.2007.21.3083.