Received: November 3, 2026
Accepted: November 18, 2026
Published: November 27, 2026

Acad Med J 2026;6(3):219-226
UDC: 616.441-008.61-07
Case report

UNILOBAR GRAVES' DISEASE IN A BILOBAR THYROID GLAND: A CASE REPORT

Pop Gjorcheva Daniela[1], Nikolovski Filip[1],
Manevska Nevena[1], Stojanoski Siinisha[1], Bitoska Iskra[2]

[1]Institute of Pathophysiology and Nuclear Medicine, Faculty of Medicine,
Ss. Cyril and Methodius University, Skopje, Republic of North Macedonia
[2]University Clinic for Endocrinology, Diabetes and Metabolic Diseases, Faculty of Medicine,
Ss. Cyril and Methodius University, Skopje, Republic of North Macedonia
e-mail: dpopgjorcheva@gmail.com

Abstract

Introduction: We report an extremely rare case of unilobar Graves' disease, affecting only one of the thyroid lobes, with intact contralateral side.

Case report: A 19-year-old female patient, with Burkitt lymphoma (being in remission for the last 2 years), was referred at our department due to rapidly growing right-sided cervical mass along with major symptoms of hyperthyreosis. The ultrasound examination revealed the right thyroid lobe enormously enlarged, diffusely hypoechogenic, highly hypervascularised, while the left lobe appeared small, isoechogenic and normally vascularised. No thyroid nodes or enlarged lymph nodes were noted. Thyroid scintigraphy with ^{99m}Tc showed diffusely, two to three-fold enlarged right lobe with preserved shape and extremely increased radioisotope uptake, along with shrunked, almost invisible left thyroid lobe. Graves' hyperthyroidism was confirmed biochemically: FT4>77.2(11-25pmol/L), FT3=38.6(2.8-6.5pmol/l), TSH<0.07(0.4-4.5mIU/L), TRAB=6.88 (0-1.5IU/L) and aTPO = 875 (<35kIU/L). Thyroid lymphoma with diffuse lobar spreading was excluded with fine needle aspiration biopsy of the right thyroid lobe. Euthyreosis and normalization of TRAB were achieved soon after the applied thyrostatic therapy.

Conclusion: Unilobar Graves' disease in bilobar thyroid gland is intriguing and may be explained by interlobar difference of TSH-R cleavage, Na/I pump expression, lymphatic drainage or different influence of specific cytokine release. In everyday practice it presents diagnostic and therapeutic challenge for clinicians, when evaluating unilateral cervical masses and hyperthyroidism.

Keywords: Graves' disease, unilobar, hyperthyroidism, thyroid ultrasound, thyroid scintigraphy

Introduction

Graves' disease is an organ-specific autoimmune disorder that almost always diffusely affects both lobes of a bilobar thyroid gland. Circulating TSH receptor autoantibodies (TRAB), that mimic TSH action, are responsible for occurrence of hyperthyroidism, diffuse bilobar goiter, orbito- and dermopathy. A variety of clinical symptoms and signs, as well as laboratory findings of thyroid hormones excess and high

values of TRAB, along with diffusely enhanced ^{99m}Tc uptake in both thyroid lobes are diagnostic milestones of Graves' disease.

Unilobar Graves' disease is an exceptionally rare condition of autoimmune affection of only one thyroid lobe, with only a few cases reported in the literature[1-15]. Rarely, Graves' disease can develop in thyroid hemiagenesis, or after lobectomy in the contralateral intact lobe, while enhanced unilateral ^{99m}Tc uptake is a typical thyroid scan appearance of a large autonomously functioning thyroid node. Hence, exact recognition of unilateral Graves' disease is a real diagnostic challenge for clinicians - its autoimmune pathogenesis originating from affection of one thyroid lobe, with intact contralateral lobe of the same thyroid gland, could be elucidated by performing all the thyroid diagnostic procedures: thyroid hormones and immunologic laboratory parameters, thyroid ultrasound (US), B and Doppler mode and ^{99m}Tc thyroid scintigraphy and occasionally, fine needle aspiration biopsy (FNAB).

We present a patient with Graves' disease affecting the right thyroid lobe with intact left lobe, focusing on possible morpho-functional differences between the lobes obtained with both, US and thyroid scintigraphy. Our patient is the only patient that has been documented during a long-lasting and very intensive thyroid practice at our institutions. Our intention is to emphasise a need for implementation of all available diagnostic modalities in evaluation and management of patients suspected for unilateral Graves' disease in order to apply most effective therapy.

Case report

A 19-year-old female patient was referred by a hematologist at our Thyroid Department because of a rapidly enlarging remarkable right-sided cervical mass, accompanied by extremely fast and profound weight loss (20 kg/ 1 month). The patient had a history of Burkitt lymphoma, treated with chemotherapy, being in remission for the last 2 years. Clinical examination of the patient revealed a presence of plenty of symptoms and signs of hyperthyroidism (weight loss despite the good appetite, heat intolerance, anxiety, intestine irritability, hair loss, eye lid retraction, tachycardia, skin vasodilatation, enhanced sweating). Neck palpation showed right thyroid lobe enlargement of nearly 2-3-fold above normal range, in opposite to left lobe which was impalpable. No enlarged lymph nodes were detected. Thyroid ultrasound showed the presence of a bilobar thyroid gland with enormously and diffusely enlarged right thyroid lobe (30x40x85 mm), with hypoechogenic and strongly hypervascularized tissue (on Doppler mode) and on the contrary to the right lobe - shrunken (14x12x30 mm), isoechogenic and normally vascularised left thyroid lobe (Figures 1 and 2).

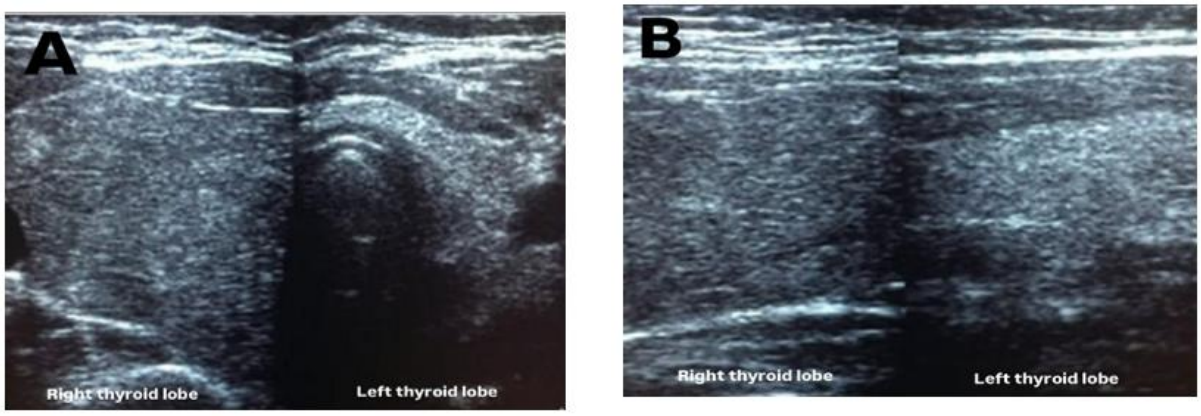

Fig. 1. Ultrasonography of transverse (A) and sagittal (B) section of the right thyroid lobe (left picture) and left thyroid lobe (right picture) from the patient's initial evaluation: The

right thyroid lobe is enlarged, diffusely hypoechoic compared to the left thyroid lobe which is with normal size and echogenicity

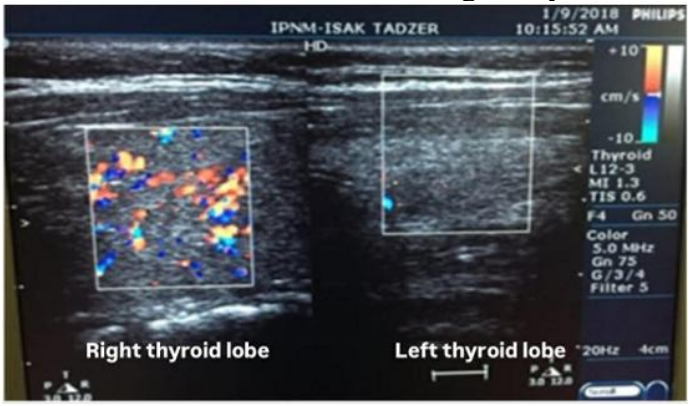

Fig. 2. Ultrasonographic Doppler sagittal section of the right thyroid lobe (left picture) and left thyroid lobe (right picture) from the patient's initial evaluation. The right thyroid lobe shows markedly pronounced vascularisation compared to the left lobe which has low vascularisation

No thyroid nodule and no enlarged lymph nodes were seen on US. Thyroid scin tigraphy with $^{99m}TcO^{4}$- showed a diffusely, 2-3-fold enlarged right lobe with preserved shape and contour, an extremely increased uptake of the radioisotope with visible pyramidal lobe. The left lobe was almost invisible, with relative $^{99m}TcO^{4}$- uptake <1% (compared to 99% right lobe) (Figure 3). Hyperthyroidism was confirmed by patient's laboratory results: high levels of FT4>77.2(11-25pmol/L), FT3=38.6(2.8-6.5 pmol/l), suppressed levels of TSH<0.07(0.4-4.5 mIU/L), and autoimmune mechanism of the thyroid dysfunction was confirmed by the high

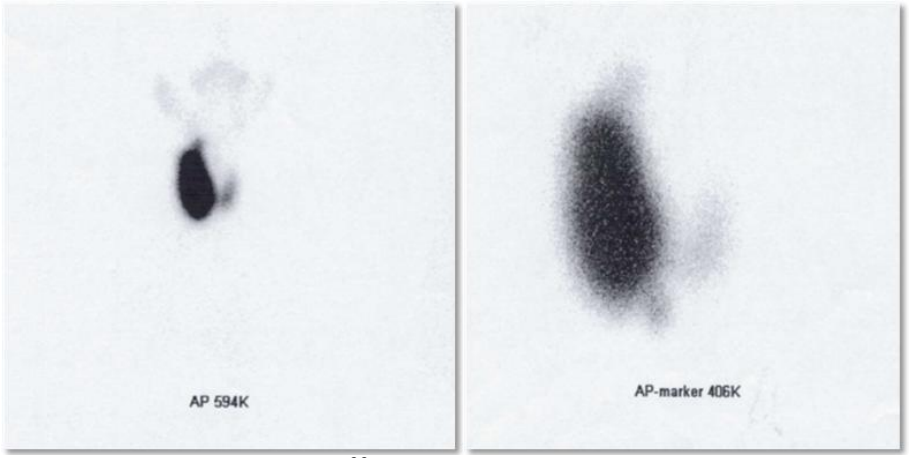

Fig. 3. Thyroid scintigraphy with ^{99m}Tc from the patient's initial evaluation showing diffusely heightened uptake of the radioisotope in the right thyroid lobe, while the left thyroid lobe has a diffusely low radiotracer uptake

values of TRAB (6.88 IU/L,normal range 0-1.5IU/L) and aTPO (875kIU/L, normal range <35kIU/L) (Table 1). Concerning the possibility of relapse of lymphoma or occurrence of thyroid lymphoma in diffusely enlarged right thyroid lobe in the absence of the enlarged cervical lymph nodes, FNAB was done. Cytological findings were congruent with Hashimoto thyroiditis, based upon the presence of benign thyrocytes with follicular arrangement and features of Hurthle cell metaplasia, with lymphoid reactive population (mature lymphocytes,

centroblasts, centrocytes and eosinophilic neutrophills). Soon after the applied thyrostatic therapy (methimazole), euthyreosis was achieved (FT_4=8.8 pmol/L, TSH=0.25 mIU/L) with normalized levels of TRAB=0.28 IU/L. Since the patient was in her reproductive period of life, her thyroid status was consistently followed; she was taking regular antithyroid medication (alternating between methimazole and PTU during her pregnancies) with only slight regression of the right-sided goiter. She had successfully completed two pregnancies and both times gave birth to healthy children. Currently, she is still being followed at our Thyroid Department, achieving remission during the last two year (Table 2).

Table 1. Laboratory findings from the patient's initial evaluation showing primary hyperthyroidism (High FT3, FT4 and supressed TSH) caused by Graves' disease (Positive TRAB)

Parameter	Result	Reference range	Unit
FT4	>77,2	11.0-25.0	pmol/L
FT3	38.6	2.8-6.5	pmol/L
TSH	<0.07	0.4-4.5	mIU/L
TRAb	6.88	0-1.5	IU/ml
aTPO	875	<35	kIU/L
aTG	145	<20	IU/ml

Table 2. Laboratory findings from the patient's follow-up in 2025 showing euthyroid status with positive aTPO and aTG antibodies congruent with Hashimoto thyroiditis

Parameter	Result	Reference range	Unit
FT3	4.95	2,8 – 6,5	pmol/L
FT4	17.76	11.0 – 25.0	pmol/L
TSH	0.847	0.4 – 4.5	mIU/L
TRAb	0.25	0-1,5	IU/ml
aTPO	>1000	<35	kIU/L
aTG	268	<20	IU/ml

Discussion

The first documented case of this incredibly rare variant of Graves' disease, reported by Sakata *et al.*, dates back to 1993[1]. In the following three-decade period, this rarity has again been confirmed by the publishing of multiple cases of unilateral Graves' disease by different authors around the world[2-15]. During this period, an increase of the number of scientific reports that aspire to shed light on the immunologic mechanism of the selective unilateral involvement of the thyroid gland has also been noted[3,6,9,13,16-20].

The pathophysiology of Graves' disease involves the production of circulating antibodies that bind to specific epitopes on the thyroid-stimulating hormone receptor (TSH-R). Binding of these antibodies to their receptor results in the stimulation of growth, proliferation and hormone synthesis by the thyrocytes. Numerous theories have been proposed to explain the selective unilobar affection of this autoimmune process. Most of these theories are focused on the side-to-side differences between TSH receptor density, avidity and sensitivity to the TSH-R autoantibodies[13,16-19]. All of that could be possibly explained by uneven shedding of the A subunit of the TSH-R (which triggers the autoimmune process) between the two thyroid lobes, which may lead to uneven expression of antigens, triggering T-cell responses in the two lobes (followed with conversion of B-cells to plasma cells and production of TRABs)[13,16-19]. Apart from changes in the receptor itself, there are other hypotheses as to why Graves' disease would affect only one lobe: interlobar differences

in local lymphatic constitution and drainage of the gland[3,6], presence of tertiary lymphoid tissue in the parenchyma of the affected lobe which could lead to local production of autoantibodies within the lobe[13]; reduced local blood flow in the unaffected lobe leading to decreased antibody circulation, sparing the lobe from the autoimmune process[9]. Some hypotheses are even focused on the sodium-iodine symporter (NIS) whose reduced expression in the unaffected lobe, or markedly increased expression in the affected lobe could lead to lowered or heightened response of the thyrocytes to the stimulating effect of the TSH-R autoantibodies[3]. Either TSH receptor or NIS differences between the two thyroid lobes could be explained by previous unilateral viral or bacterial inflammatory process[20], cytokine release[3], genetic or epigenetic changes to their genes.

The diagnosis of Graves' disease begins with a detailed patient history and physical examination,including thyroid palpation, skin assessment and evaluation of blood pressure and heart rate, as well as hands and fingers tremor. Palpatory findings may include diffusely enlarged thyroid gland, but normal findings cannot exclude the diagnosis of Graves' disease. The skin is often warm, diaphoretic and changes congruent with Graves' dermopathy could be assessed pretibially. Regarding heart function, tachycardia and hypertension could also be noted. The next diagnostic step is usually ultrasonography of the cervical region. In cases of Graves' disease, findings may range from normal-sized, isoechoic thyroid parenchyma of both lobes, to a diffuse and bilobar enlargement of the thyroid with hypoechoic, heterogeneous parenchymal structure with markedly increased vascularisation.Ultrasonography is helpful to differentiate Graves' disease from other causes of hyperthyreosis such as toxic thyroid nodule or multinodular goiter. However, scintigraphy of the thyroid gland is needed to confirm Graves' disease based upon characteristically enlarged gland with diffusely increased radiotracer uptake, which excludes toxic thyroid nodules and multinodular goiter from the differential diagnosis. Hormone panel studies and serology finally confirm the diagnosis of primary hyperthyroidism (suppressed TSH, and high FT3 and FT4 concentrations) caused by Graves' disease (increased TSH-R autoantibodies concentration).

In the diagnosis of unilateral Graves' disease, the challenge is to locate the disease in only one of the lobes based on morphofunctional differences between the two lobes, along with confirmationthat those differences are indeed caused by Graves' disease.

Our patient was referred to our institutions by her hematologist for evaluation of a fast-growing mass in her cervical region. Palpatory findings revealed a 2-3 fold right lobe increase while the left lobe was impalpable. During the physical examination, advanced symptoms of hyperthyreosis were noted. Laboratory findings revealed advanced hyperthyreosis with suppressed TSH concentrations and high concentrations of TSH-R autoantibodies and anti-TPO antibodies. Ultrasonography revealed a diffusely enlarged, hypoechoic, markedly vascularised right lobe without presence of thyroid nodules, while the left lobe was slightly shrunken, isoechoic with normal vascularisation. This morphological difference between the two lobes was functionally confirmed by the thyroid scan which revealed an increased ^{99m}Tc uptake in diffusely enlarged right thyroid lobe with presence of lobus pyramidalis (characteristic for Graves' disease) with minimal radiotracer uptake in the opposite left lobe-markedly lower uptake and size compared to the right lobe.The ultrasound findings and the scan definitively excluded thyroid hemiagenesis, single or multinodular toxic goiter.

In conclusion, the diffusely enlarged, hypoechoic, hypervascularised right thyroid lobe with diffusely increased radiotracer uptake along with markedly high concentrations of TSH-R antibodies, coupled with the shrunken, isoechoic, hypovascularised left lobe with minimal radiotracer uptake gave reason for suspicion for the presence of unilateral Graves' disease in the right thyroid lobe. Finally, the fine needle aspiration biopsy (FNAB) that was indicated to exclude the slight possibility of lymphoma relapse in the right lobe were

congruent with Hashimoto thyroiditis, which even further proved the autoimmune inflammatory nature of the disease.

We reviewed all published case reports and articles describing unilateral Graves' disease. Table 3 presents the published case reports and case report series, along with the diag nostic and therapeutic protocol used by the authors, as well as the outcome of applied diagnostic and

Table 3. Literature data on published cases with applied diagnostic, therapeutic procedures and treatment outcomes

Year	Author/s	Lobe	Diagnostic methods	Treatment	Outcome
1993	Sakata,*et al*.[1]	NS	Scintigraphy (^{99m}Tc, ^{123} I)	Hemithyroidectomy	Relapse in unaffected lobe
1999	Dimai,*et al*.[2]	Right	Ultrasound (US), ^{123}I scintigraphy, FNAB, Serology	NS	NS
2004	Gratz,*et al*.[3]	NS	US, Scintigraphy, FNAB, serology	Antithyroid therapy	NS
2006	Bolognesi & Rosi[4]	Right	US, Scintigraphy, Serology	Methimazole	Euthyroid for 12 months
2007	Kısakol,*et al*.[5]	Right (2)	US, Scintigraphy, Serology	PTU, Antithyroid therapy	Remission after 12 months
2010	Al Juhanni N,*et al*.[6]	Right	US, scintigraphy	NS	NS
2011	Gonulalan & Cakir[8]	Right	US, Scintigraphy	Anti-thyroid therapy	NS
2011	Chen & Green[9]	Left	US, Scintigraphy, serology	NS	NS
2015	Eklioglu BS, *et al*.[10]	Left	US, scintigraphy, serology	Anti-thyroid therapy	Remission after 10 months
2016	AY SA *et al*.[11]	Right	US, scintigraphy, serology	Anti-thyroid therapy	Remission, then relapse
2019	Pande *et al*.[12]	Left	US, scintigraphy, serology	Antithyroid therapy	Remission after 10 months
2019	Manthri *et al*.[13]	8R, 7L	US, scintigraphy	Antithyroid drugs, ^{131} I	Remission
2023	Alaybaa & Alhuzaim[14]	Left	US, scintigraphy, serology	Anti-thyroid therapy	Improveme nt
2023	Alzedaneen Y, *et al*.[15]	Right	US, scintigraphy, serology	Hemithyroidectomy	Remission

*NS- Not Specified

treatment protocols. Based on this review, we can conclude that our diagnostic approach was in line with those reported in all previously published cases. This diagnostic protocol included patient history and physical examination, ultrasonography of the thyroid gland, thyroid scintigraphy, hormone panel, serology and FNAB. By using these diagnostic steps, unilateral Graves' disease can be securely diagnosed, with exclusion of every possible differential diagnosis.By interpreting the patient's medical history and physical examination, hyperthyreosis may be suspected. The ultrasound evaluation can even further support the correct diagnosis and help exclude several major differential diagnoses, such as thyroid hemiagenesis, toxic thyroid nodule and toxic multinodular goiter. The ^{99m}Tc pertechnetate scan can confidently exclude the same differential diagnoses,and identify other causes of

thyrotoxicosis, such as subacute thyroiditis, as well as strengthen the suspicion of Graves' disease by giving us a functional image of the affected thyroid lobe. Laboratory findings confirming the presence of primary hyperthyrodism and serology with positive TSH-R antibodies led us to establish the final correct diagnosis - Graves' disease with unilateral involvement. If indicate, FNAB could further provide evidence of the inflammatory nature of the disease.

The treatment for Graves' disease usually includes anti-thyroid medication such as methimazole, thiamazole and propylthiouracil, along with radioiodine therapy and surgical excision. The choice of therapy depends on the patient's age, comorbidities, severity of disease and presence of Graves' orbitopathy. Our patient was treated with anti-thyroid therapy (methimazole), following a propylthiouracil treatment during which she had two pregnancies and gave birth to two healthy babies. During treatment, the palpatory and US findings in the right lobe were regressing, eliminating the need for surgical treatment, which would have been justified in the presence of Graves' orbitopathy that was not the case with our patient. Radioiodine therapy was not an option because of the patient's young age and previous history of Burkitt lymphoma. Furthermore, the regression of the disease (stable euthyroid state while on anti-thyroid medication with decreasing levels of TRAB) and concomitant progression of Hashimoto thyroiditis with rising aTPO and aTG levels, raises the possibility of sustained remission of the disease with potential development of hypothyreosis. In the period 2024-2026, the patient has been in remission, confirmed by low TSH-R antibody levels, and continuous rising levels of aTPO and aTG.

Based on the analyzed literature, we observed an identical therapeutic approach, predominantly involving anti-thyroid medicamentous treatment, which led to remission in most of the cases.

Conclusions

Unilateral involvement of a bilobar thyroid gland is a very rare form of Graves' disease which appears because of differences in the extracellular cleavage mechanisms of the TSH-R, differences in the lymphatic drainage of each thyroid lobe or is influenced by specific cytokine release.The challenging aspect of the diagnostic process is the confirmation of the disease in only one thyroid lobe, as it almost exclusively affects both lobes of the thyroid gland. Therefore, a comprehensive palette of diagnostic tools is needed for establishing an exact diagnosis, which must include thyroid ultrasonography, both B and Doppler mode, thyroid scintigraphy and serology. It is only by integrating these diagnostic methods can clinicians exclude every other possible aetiology and prove the diagnosis with high degree of certainty.

Conflict of interest statement. None declared.
Written consent of the patients was obtained.

References

1. Sakata S, Fuwa Y, Goto S, Fukui M, Yuasa H, Takuno H, *et al*. Two cases of Graves' disease with presentation of unilateral diffuse uptake of radioisotopes. *J Endocrinol Invest* 1993; 16(11): 903-907. doi: 10.1007/BF03348954.
2. Dimai HP, Ramschak-Schwarzer S, Lax S, Lipp RW, Leb G. Hyperthyroidism of Graves' disease: evidence for only unilateral involvement of the thyroid gland in a 31-year-old female patient. *J Endocrinol Invest* 1999; 22(3): 215-219. doi: 10.1007/BF03343545.

3. Gratz S, Barth P, Arnold R, Behr TM. Graves' disease with unilateral radioisotope uptake. *Nuklearmedizin* 2004; 43(5): N66-N68. PMID: 15536692.
4. Bolognesi M, Rossi R. Unilateral Graves' disease. *Thyroid* 2006; 16(5): 493-495. doi: 10.1089/thy.2006.16.493.
5. Kısakol G, Çakır M, Güngör K, Gönen MS. Two cases of Graves' disease presenting with unilateral involvement of the thyroid gland. *Endocrinol Res Pract* 2007; 11(2): 64-66.
6. Al Juhanni N, Wagieh Sh, AI Ghamdi H. Graves' Disease Affecting one Thyroid lobe (Unilateral Graves' Disease): Case Report. *Egyptian J Nucl Med* 2010; 2(1): 62-65. doi 10.21608/egyjnm.2010.5501.
7. Wagih S. Graves' disease affecting one thyroid lobe (unilateral Graves' disease): case report. *Egypt J Nucl Med*. 2010;3(3):62–65. doi: 10.21608/egyjnm.2010.5501.
8. Gönülalan G, Çakır M. Graves' disease with unilateral involvement: a rare entity. *Endocrinol Res Pract* 2011; 15(4): 128-129. https://endocrinolrespract.org/index.php/pub/article/view/607.
9. Chen LC, Green JB. First reported case of unilateral Graves' disease in the left lobe of a bilobar thyroid gland. *Thyroid* 2011; 21(6): 683-686. doi: 10.1089/thy.2010.0343.
10. Eklioglu BS, Atabek ME, Akyurek N, *et al*. Unilateral Graves' disease in an adolescent: case report. *ESPE Abstracts* 2015; 84: P-3-1219.
11. Ay SA, Baskoy K, Urhan M, *et al*. A rare variant of hyperthyroidism: unilateral Graves' disease. *Endocrine Abstracts* 2016; 41: EP386.
12. Pande A, Aggarwal A, Wadhwa R. Unilateral Graves' disease: a rare variant. *J Clin Diagn Res* 2019; 13(9): OD06-OD08. doi: 10.7860/JCDR/2019/42313.13147.
13. Manthri RG, Ajit N, Vaikakkara S, Devi BV, Kalawat T. Unilateral Graves' disease: the lesser known. *Indian J Nucl Med* 2019; 34(2): 96-98. doi: 10.4103/ijnm. IJNM_11_19.
14. Alaybaa K, Alhuzaim O. Unilateral Graves' disease in a bilobar thyroid gland: a very unusual cause of hyperthyroidism. *JCEM Case Rep* 2023; 1(3): luad048. doi: 10.1210/jcemcr/luad048.
15. Alzedaneen Y, Moxley MC, Reddy R, Munir KM. Unilateral thyroid lobe involvement of Graves' disease. *JCEM Case Rep* 2023; 1(2): luad023. Doi: 10.1210/jcemcr/luad023.
16. Chen CR, Pichurin P, Nagayama Y, Latrofa F, Rapaport B and McLachlan SM. The thyrotropin receptor autoantigen in Graves disease is the culprit as well as the victim. *The Journal of Clinical Investigation* 2003;111(12): 1897-1904.
17. Rapoport B, McLachlan SM. TSH receptor cleavage into subunits and shedding of the A-subunit; a molecular and clinical perspective. *Endocr Rev* 2016; 37(2): 114-134. doi: 10.1210/er.2015-1098.
18. Morshed SA, Davies TF. Graves' disease mechanisms: the role of stimulating, blocking, and cleavage region TSH receptor antibodies. *Horm Metab Res* 2015; 47(10): 727-734. doi: 10.1055/s-0035-1559633..
19. Vieira IH, Rodrigues D and Palva I. The Mysterious Universe of the Receptor. Front Endocrinol (Lausanne) 2022; 13: 944715. doi: 10.3389/fendo.2022.944715.
20. Tomer Y. Davies TF. Infection, thyroid disease and autoimmunity. *Endocr Rev* 1993; 14(1): 107-120. doi: 10.1210/edrv-14-1-107.